Mitral Valve Prolapse Associated with Atrial Level Communication

SHI-MIN YUAN[1] and JACOB LAVEE[2]

From [1]Department of Cardiothoracic Surgery, Affiliated Hospital of Taishan Medical College, Taian, Shandong Province, People's Republic of China; [2]Department of Cardiac and Thoracic Surgery, The Chaim Sheba Medical Center, Tel Hashomer, Israel

YUAN and LAVEE: ***Mitral Valve Prolapse Associated with Atrial Level Communication*****. Objectives:** *The association of mitral valve disorder and atrial communication, either atrial septal defect or patent foramen ovale, remains a topic of debate over time. The aim of the present article is to describe the clinical features of this entity.* **Patients and Methods:** *Eighteen patients with an atrial communication that required closure were selected into this study, and were divided into two groups: Group A patients were associated with mitral valve prolapse, and Group B patients were not.* **Results:** *Pulmonary hypertension was noted in eight patients of Group A, and in one patient of Group B. Three patients in Group A and none of Group B had infective endocarditis. Group A patients had larger left ventricular diastolic dimension, left atrial dimension, and tricuspid valve peak systolic pressure gradient than Group B patients. Regression analysis revealed an inverse relationship between left ventricular diastolic dimension and peak systolic pressure gradient across the tricuspid valve in Group A (p=0.033), but no significant correlation was noted in Group B (p=0.183).* **Conclusions:** *The presence of mitral valve prolapse with various degrees of mitral regurgitation in the patients with atrial level communication may implicate an impaired diastolic function of the left ventricle, and increased pulmonary artery pressure. Surgical intervention to the atrial level communication and mitral regurgitation may lead to a better prognosis in such patients. (J HK Coll Cardiol 2011;19:57-62)*

Heart septal defects, atrial; Hypertension, pulmonary; Mitral valve prolapse; Ventricular function, left

摘要

目的：二尖瓣病變合併心房水平分流（心房中隔缺損或未閉卵圓孔）是長期以來一個存在爭議的問題。本文著重討論該症的臨床特點。**方法：**１８例需要閉合心房水平分流的患者被列入本研究，並分成兩組：A 組患者合併二尖瓣脱垂，B 組不合併二尖瓣脱垂。**結果：**A 組中8 例患者有肺動脈高壓，B 組中1 例患者有肺動脈高壓。A 、B 兩組中各有3 例患者有感染性心內膜炎。A 組的左室舒張期內徑、左房內徑及經三尖瓣的峰值壓力階差顯著大於B 組。回歸分析結果顯示A組左室舒張期內徑與經三尖瓣的峰值壓力階差之間具有顯著的負相關（p＝0.033），而B組該兩參數間則無顯著關聯性（p＝0.183）。**結論：**在心房水平分流的患者，二尖瓣脱垂伴不同程度的二尖瓣返流可能會使左室的舒張功能受損、肺動脈壓力增加。對心房水平分流及二尖瓣返流的外科治療會使此類患者獲得較好的預後。

關鍵詞：心房中隔缺損，肺動脈高壓，二尖瓣脱垂，左心室功能

Address for reprints: Dr. Shi-Min Yuan
Department of Cardiothoracic Surgery, Affiliated Hospital of Taishan Medical College, 706 Taishan Street, Taishan District, Taian 271000, Shandong Province, People's Republic of China

Email: s.m.yuan@v.gg

Received June 19, 2011; revision accepted September 29, 2011

Introduction

The association of mitral valve disorder and atrial septal defect (ASD) or patent foramen ovale remains a topic of debate over time. Mitral valve prolapse that was associated with secundum ASD was regarded as compatible to congenital lesion in some young children,[1] but could be a rheumatic disorder in young adults.[2] Due to the fact that right ventricular volume loading and dilation, as well as paradoxical septal movement, mitral valve prolapse in patients with an ASD was surmised to be functional.[3]

Patients and Methods

From January 2004 to June 2008, 41 adult patients with an atrial communication (secundum ASD or patent foramen ovale) received an ASD/patent foramen ovale closure solely or combined with other cardiac operations in this department. Eighteen patients with or without mitral valve prolapse were sorted out and were included into this study. The exclusion criteria were,

1. mitral stenosis, or predominant mitral stenosis mixed with mitral regurgitation;
2. flail mitral valve caused by acute mitral chordae rupture;
3. a redo cardiac operation and the atrial level communication had been closed in the primary operation;
4. primum atrial septal defect with mitral cleft;
5. associated with other complex congenital heart defects.

Group A included 11 patients with mitral valve prolapse associated with coronary artery disease, atrial fibrillation, infective endocarditis and anemia. Seven patients without mitral valve prolapse were involved into Group B as control. Informed consent was obtained from the study participants, and the study was approved by institutional ethical committees.

The degree of severity of mitral regurgitation can be quantified by the regurgitant fraction, which is the percentage of the left ventricular stroke volume that regurgitates into the left atrium. Methods that have been used to assess the regurgitant fraction in mitral regurgitation included echocardiography, cardiac catheterization, computed tomography, and cardiac magnetic resonance imaging. Regurgitant fraction <20%, 20-40%, 40-60% and >60% was defined as mild, moderate, moderate to severe, and severe mitral regurgitation, respectively.[4]

Pulmonary hypertension was defined as a mean pulmonary arterial pressure of greater than 25 mmHg at rest or greater than 30 mmHg during exercise. Based on the normal values of right ventricular systolic pressure (<35 mmHg) and tricuspid regurgitant velocity (<2.7 m/s), mild pulmonary arterial hypertension was defined when right ventricular systolic pressure was 36-50 mmHg, or tricuspid regurgitant velocity was 2.8-3.4 m/s, and moderate-severe pulmonary arterial hypertension was defined when right ventricular systolic pressure >50 mmHg, or tricuspid regurgitant velocity >3.4 m/s.[5]

Comparative study was conducted between the two groups in terms of age, ASD size, and echocardiographic measurements, including left ventricular function, left atrial diameter, tricuspid valve peak systolic pressure gradient, and right atrial pressure. Data were expressed as mean±SD. Unpaired *t*-test, Fisher's exact test, and linear regression were applied. $p<0.05$ was considered of statistical significance.

Results

The demographics of the patients were listed in Table 1. In systole, the thickened scallop of the posterior mitral valve leaflet prolapsed beyond the annular plane into the left atrium was seen by echocardiography in each patient of Group A. The severity of mitral regurgitation of Group A patients was mild, moderate, moderate-to-severe, and severe secondary to mitral valve prolapse in 4 (36.4%), 2 (18.2%), 2 (18.2%), and 3 (27.3%) patients, respectively. There were no mitral valve disorders in Group B patients. No difference was noted in patients' age and ASD size between the two groups. Pulmonary hypertension was noted in eight patients of Group A, and in one patient of Group B. Three patients in Group A and none of Group B had

Table 1. Demographic data

Parameters	Group A	Group B	*p* value
Case, n	11	7	–
Female gender, n (%)	4 (36.4)	2 (28.6)	1.0000
Age, year	56.00±13.25	55.00±12.83	0.8765
Prolapse valve mitral, n (%)	11 (100)	0 (0)	<0.0001
Mild MR, n (%)	4 (36.4)	–	–
Moderate MR, n (%)	2 (18.2)	–	–
Moderate to severe MR, n (%)	2 (18.2)	–	–
Severe MR, n (%)	3 (27.3)	–	–
ASD, n (%)	4 (36.4)	4 (57.1)	0.6305
Patent foramen ovale, n (%)	7 (63.6)	3 (42.9)	0.6305
ASD/patent foramen ovale size, cm	1.4636±1.5042	1.6929±1.1798	0.7377
Patch repair of ASD, n (%)	3 (27.3)	3 (42.9)	0.6267
Mitral valve repair, n (%)	5 (45.5)	–	–
Mitral valve replacement, n (%)	6 (54.5)	–	–
Pulmonary hypertension, n (%)	8 (72.7)	1 (14.3)	0.0498
Infective endocarditis, n (%)	3 (27.3)	0 (0)	0.2451
Ischemic heart disease, n (%)	0 (0)	0 (0)	1.0000
Mellitus diabetes, n (%)	2 (18.2)	1 (14.3)	1.0000
Hypertension, n (%)	3 (27.3)	2 (28.6)	1.0000

ASD: atrial septal defect; MR: mitral regurgitstion.

infective endocarditis.

Of the echocardiographic measurements, statistical significance was found in left ventricular diastolic dimension, left atrial dimension, and tricuspid valve gradient between the two groups. No intergroup difference was noted in left ventricular systolic dimension, interventricular septum in diastole, left ventricular posterior wall thickness in diastole, estimated left ventricular mass index, and estimated right atrial pressure (Table 2). Regression analysis revealed a close inverse relationship between left ventricular diastolic dimension and peak pressure gradient across the tricuspid valve in Group A (p=0.033) (Figure 1), but no significant correlation in Group B (p=0.183) (Figure 2). All the patients survived and were well in both groups.

Discussion

Mitral valve prolapse is the most common congenital valvular heart disease in adults. The prevalence of mitral valve prolapse in the United States has been estimated at four to five percent, but varies by age and gender. The prolapse of the mitral valve involves superior and posterior displacement of one or both mitral valve leaflets across the plane of the mitral valve annulus into the left atrium during systole.[6] Mitral valve prolapse is classified as primary, secondary, or functional based upon the anatomic or physiologic defects. Although the prognosis is usually benign, mitral valve prolapse can be associated with serious complications, including mitral regurgitation, infective endocarditis and arrhythmias.[6]

Table 2. Hymodynamics of the patients with versus without mitral valve prolapse

Parameters	Group A	Group B	*p* value
Left ventricular ejection fraction (%)	56.11±9.28 (35-65)	58.57±5.56 (50-65)	0.5467
Left ventricular diastolic dimension (cm)	5.0900±0.8543 (3.9-6.1)	4.1871±0.5849 (3.5-5.41)	0.0317
Left ventricular systolic dimension (cm)	3.1044±0.5242 (2.5-3.85)	2.6657±0.5349 (2.2-3.58)	0.1220
Interventricular septal thickness in diastole (cm)	1.0533±0.1539 (0.8-1.3)	1.0971±0.1468 (0.9-1.3)	0.5738
Left ventricular posterior wall thickness in diastole (cm)	1.0211±0.0867 (0.9-1.15)	1.0229±0.1643 (0.7-1.16)	0.9784
Estimated left ventricular mass index (g/m^2)	106.238±30.027 (62.2-139)	87.367±28.906 (56.5-137.2)	0.2601
Left atrial diameter (cm)	4.8778±1.0008 (3.4-5.74)	3.9271±0.6581 (2.9-4.7)	0.0480
Peak gradient across the tricuspid valve (mmHg)	46.1625±8.6560 (42.3-61)	27.8900±11.4061 (8-39)	0.0051
Estimated right atrial pressure (mmHg)	10.00±4.63 (5-15)	8.33±6.06 (5-20)	0.5690

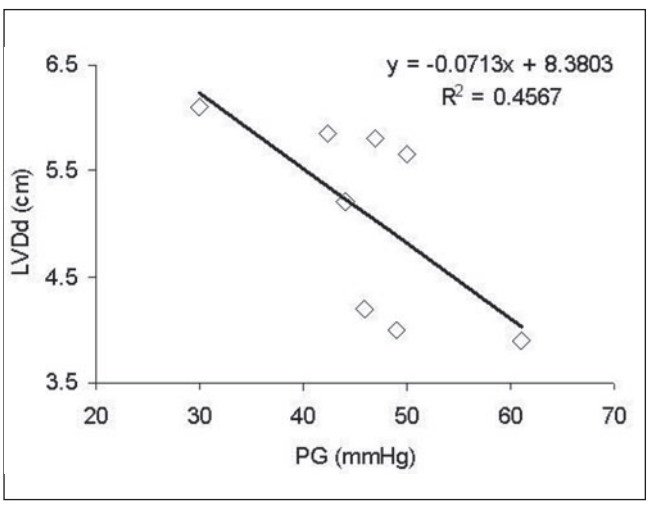

Figure 1. *Regression analysis revealed an inverse relationship between the left ventricular diastolic dimension and peak systolic pressure gradient across the tricuspid valve in Group A (p=0.033). LVDd=left ventricular diastolic dimension; PG =peak systolic pressure gradient across the tricuspid valve.*

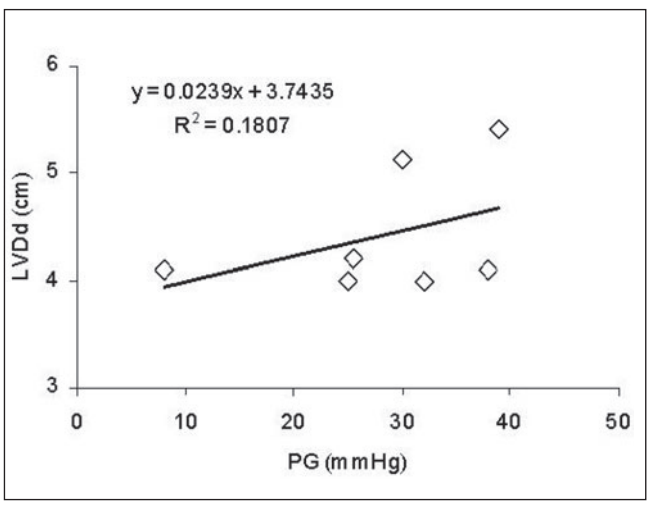

Figure 2. *No significant correlation was noted between left ventricular diastolic dimension and peak systolic pressure gradient across the tricuspid valve in Group B (p=0.183). LVDd=left ventricular diastolic dimension; PG=peak systolic pressure gradient across the tricuspid valve.*

The incidence of the association of mitral valve prolapse and secundum atrial septal defect is increasing, and has led to much deliberation over the years.[3] This entity was regarded as benign, but prognosis of mitral valve malfunction exists, and infective endocarditis might occur as a complication of secundum ASD.[7] The risk of infective endocarditis in patients with isolated ASD of the fossa ovalis type is exceedingly small, but it may develop with the associated mitral valve disorder, especially prolapse of posterior mitral leaflet.[8] The development of mitral valve prolapse would alter the prognosis of ASD.[9] And mitral valve prolapse could, in turn, regress after ASD closure.[3]

Our results based on echocardiographic hemodynamics showed a similar trend with those of Burleson et al,[10] who noted patients with mitral valve prolapse had a greater pulmonary artery pressure preoperatively than those without (102±19 vs. 84±21 mmHg). No significant differences were noted in mitral annulus dimensions or left ventricular chamber areas. Kestlli[3] obtained an extensive significance in a comparative study on mitral valve prolapse. He found that patients with an ASD had decreased values of diastolic ventricular septum thickness and diastolic left ventricular posterior wall thickness, but ejection fraction was high, when comparing with those patients without mitral valve prolapse. The development of mitral valve prolapse was explained by a theory of imbalanced stability of a triangle formed by mitral leaflet, papillary muscle-chord, and left ventricular wall. Patients with an ASD yielded mitral valve prolapse due to a better left ventricular filling and a higher left ventricular ejection fraction.[3] His novel explanation has furnished considerable evidence for the understanding of this entity.

We noted a significant correlation between left ventricular diastolic dimension and peak pressure gradient across the tricuspid valve in patients with mitral valve prolapse (Group A) but not in patients with no mitral valve disease (Group B). However, Group B may not reach statistical significance due to small number of patients. Animal studies showed that an end-diastolic deformity in the right ventricular outflow tract may predispose the production of low early diastolic pressure in the local region.[11] The hemodynamic status of Group B patients in this study may thus represent an underlying cause of the impaired early diastolic function in the right ventricular outflow tract region.

Severe pulmonary hypertension secondary to mitral valve prolapse was very rare. Tago et al[12] reported such a rare association in a 65-year-old female patient, who had her condition improved by surgical operation with mitral valve replacement and tricuspid annuloplasty, and postoperative prostagrandin E1 proved effective for residual pulmonary hypertension. The pulmonary hypertension was considered to be related to the presence of latent left ventricular dysfunction.[13] In fact, right ventricular systolic pressure may correlate with diastolic function in other cardiovascular disease group of patients. The peak systolic pressure gradient over the tricuspid valve of 27 mmHg indicated mildly increased pulmonary pressures.[14] Morrison et al[15] observed that most of their elevated pulmonary artery pressure patients were passive elevations secondary to global or regional left ventricular dysfunction. Elevated left ventricular end-diastolic pressure was often associated with left ventricular systolic dysfunction, left ventricular hypertrophy, or pulmonary hypertension, which may predict increased perioperative mortality and morbidity.[16] These may account for why the majority of Group A patients showed pulmonary hypertension comparing to Group B patients in this study.

In conclusion, the presence of mitral valve prolapse with various degrees of mitral regurgitation in the patients with atrial level communication may implicate an impaired diastolic function of the left ventricle, and increased pulmonary artery pressure. Surgical intervention to the atrial level communication and mitral regurgitation may lead to a better prognosis in such patients.

References

1. Yuan SM. Association of secundum atrial septal defect and mitral lesion in childhood: a case report. Zhonghua Yi Xue Za Zhi (Taipei) 1997;59:308-10.
2. No authors listed. Case records of the Massachusetts General Hospital. Weekly clinicopathological exercises. Case 5-1974. N Engl J Med 1974;290:330-6.

3. Kestlli M. Mitral valve prolapse in atrial septal defect. Internet J Thorac Cardiovasc Surg 2002;5:1.
4. Mitral regurgitation. http://www.answers.com/topic/mitral-insufficiency.
5. Price LC, Wort SJ, Finney SJ, et al. Pulmonary vascular and right ventricular dysfunction in adult critical care: current and emerging options for management: a systematic literature review. Crit Care 2010;14:R169.
6. Schneider A, Sorrentino M. Definition and diagnosis of mitral valve prolapse. http://cmbi.bjmu.edu.cn/uptodate/Valvular%20and%20aortic%20disease/Mitral%20valve/Definition%20and%20diagnosis%20of%20mitral%20valve%20prolapse.htm.
7. Leachman RD, Cokkinos DV, Cooley DA. Association of ostium secundum atrial septal defects with mitral valve prolapse. Am J Cardiol 1976;38:167-9.
8. Pocock WA, Barlow JB. An association between the billowing posterior mitral leaflet syndrome and congenital heart disease, particularly atrial septal defect. Am Heart J 1971;81:720-2.
9. Jeresaty RM. Editorial: mitral valve prolapse-click syndrome in atrial septal defect. Chest 1975;67:132-3.
10. Burleson KO, Blanchard DG, Kuvelas T, et al. Left ventricular shape deformation and mitral valve prolapse in chronic pulmonary hypertension. Echocardiography 2007;11:537-45.
11. Courtois M, Barzilai B, Gutierrez F, et al. Characterization of regional diastolic pressure gradients in the right ventricle. Circulation 1990;82:1413-23.
12. Tago K, Ishikawa S, Satoh Y, et al. Mitral valve prolapse associated with severe pulmonary hypertension: a case report. Kyobu Geka 1997;50:789-91.
13. Agricola E, Bombardini T, Oppizzi M, et al. Usefulness of latent left ventricular dysfunction assessed by Bowditch Treppe to predict stress-induced pulmonary hypertension in minimally symptomatic severe mitral regurgitation secondary to mitral valve prolapse. Am J Cardiol 2005;95:414-7.
14. Kurz DJ, Oechslin EN, Kobza R, et al. Idiopathic enlargement of the right atrium: 23 year follow up of a familial cluster and their unaffected relatives. Heart 2004;90:1310-4.
15. Morrison D, Goldman S, Wright AL, et al. The effect of pulmonary hypertension on systolic function of the right ventricle. Chest 1983;84:250-7.
16. Apostolakis EE, Baikoussis NG, Parissis H, et al. Left ventricular diastolic dysfunction of the cardiac surgery patient; a point of view for the cardiac surgeon and cardio-anesthesiologist. J Cardiothorac Surg 2009;4:67.