Transvenous Dual Chamber Pacemaker Implantation via a Persistent Left Superior Vena Cava

YUI-MING LAM, CHEUK-MAN YU, CHU-PAK LAU

From Division of Cardiology, Department of Medicine, The University of Hong Kong, Hong Kong

LAM ET AL.: ***Transvenous Dual Chamber Pacemaker Implantation via a Persistent Left Superior Vena Cava.*** *A 73-year-old patient underwent dual chamber pacemaker implantation because of symptomatic second-degree heart block. During implantation, persistence of the left superior vena cava was observed. A passive fixation right ventricular lead and an active fixation right atrial lead were used with satisfactory long-term pacing and sensing result. (J HK Coll Cardiol 2002;10:94-97)*

Dual chamber pacemaker, left superior vena cava

摘要
一位 73 歲患者因 II 度房室傳導阻滯進行雙腔起搏器置入。在安置過程中，觀察到左上腔靜脈存在，並經此靜脈被動固定右室電極和主動固定右房電極，其長期起搏與感知功能良好。

關鍵詞：雙腔起搏器　　左上腔靜脈

Introduction

Persistent left superior vena cava (SVC) can cause difficulty in proper positioning of the endocardial electrode during implantation of a permanent pacing system. In this report we describe the successful implantation of a dual chamber pacemaker using a left-sided approach in a patient with persistent left SVC.

Address for reprints: Dr. Cheuk-Man Yu
Division of Cardiology, Department of Medicine, Queen Mary Hospital, The University of Hong Kong, Hong Kong

Tel: (852) 2855 3600, Fax: (852) 2818 6304

Received December 19, 2001; revision accepted February 21, 2002

Case Report

A 73-year-old gentleman with history of diabetes mellitus, hypertension, Parkinson's disease and cerebral infarction complained of recurrent episodes of dizziness. ECG showed high grade second-degree atrioventricular block and implantation of a dual chamber pacemaker was planned. A guidewire was passed through the left cephalic vein cut down under fluoroscopy guidance. It followed an abnormal course along the left border of the thoracic spine, passing through a large coronary sinus, the right atrium and entered into the right SVC, forming a large "U" shape (Figure 1). Subsequent venogram confirmed a persistent left SVC draining into the right atrium via a large coronary sinus (Figure 2). A tined bipolar ventricular lead (Model 4024, Medtronic Inc, MN, USA) was inserted and formed a loop in the right atrium. Using a highly curved stylet and with

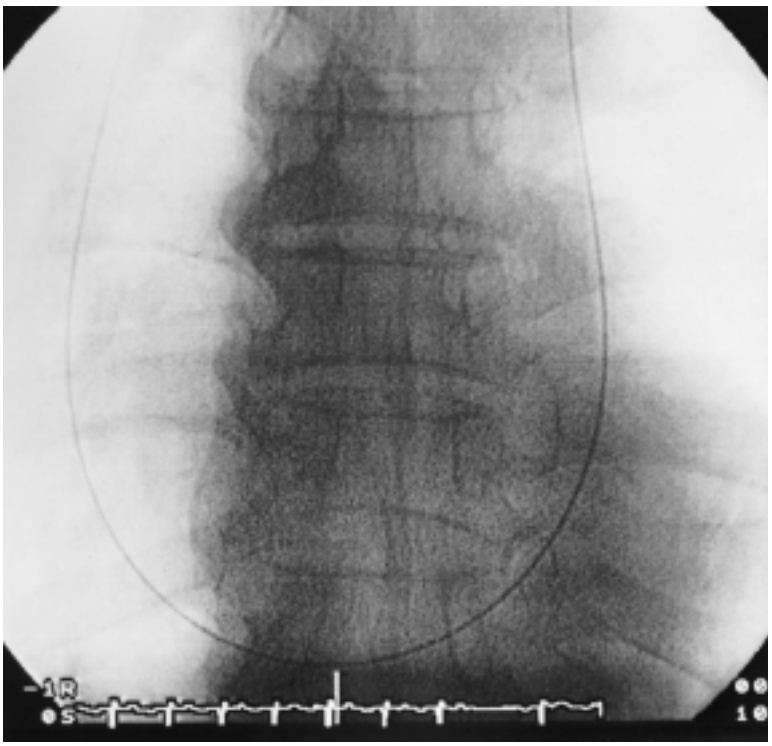

Figure 1. *A patient with persistent left superior venous cava underwent permanent pacemaker implantation. A guidewire was passed via left cephalic vein cutdown which course through the left superior venous cava to the right atrium and looping up into the right superior venous cava forming a "U" configuration.*

Figure 2. *The same patient with persistent left superior venous cava. Contrast agent was injected through the left cephalic vein revealed a large left superior venous cava connecting to the right atrium.*

further manipulation, the lead entered into the right ventricle after crossing the tricuspid valve. The stylet was then changed to a straight one. The ventricular lead was further advanced and passively fixed in the right ventricular apex. The stylet was then pulled out and the lead was carefully withdrawn to reduce the loop in the right atrium. Using a gently curved stylet, a straight bipolar atrial screw-in lead (Medtronic 4068) was actively fixed to the upper anterolateral aspect of the right atrium. A DDDR pacemaker (Model Thera DR 7960i, Medtronic Inc, MN USA) was then implanted (Figure 3). Subsequent follow up showed normal pacemaker function with stable threshold and endocardial signals (Table 1). Repeated CXR revealed stable electrode position and there was no more recurrence of symptoms.

Discussion

Persistence of the left SVC occurs in approximately 0.5% of the population.[1] It is due to the failure of development of the left innominate vein which forms a communication between the anterior cardinal veins.[2] The left anterior cardinal vein persists and continues to drain the left brachiocephalic veins into the sinus venosus and ultimately develops to a left SVC which empties into the coronary sinus. Proper

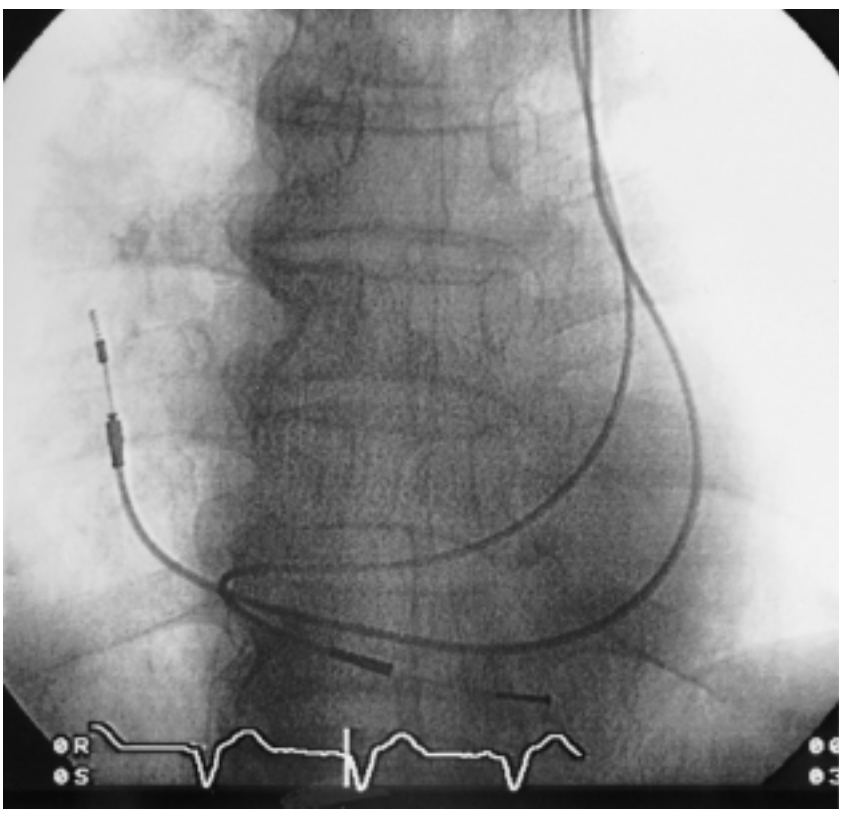

Figure 3. *The same patient with persistent left superior venous cava showing the position of the right atrial active fixation lead and the passive fixation right ventricular lead. The latter coursed through and bend at the os of the coronary sinus and engaged into the right ventricular apex.*

Table 1. Signals and thresholds at implantation and follow up

Time after implantation (months)	0	1/2	6	9	12	15
Atrial sensing (mV)	4.6	4-5.6	5.6-8	>4	2.8-4.0	2.8-4
Ventricular sensing (mV)	24.6	31.4-44.8	31.4-44.8	>11.2	22.4	31.4-44.8
Atrial threshold*: V	0.8	2.5	2.5	2.5	2.5	2.5
ms	0.5	0.06	0.09	0.09	0.09	0.09
Ventricular threshold*: V	0.1	2.5	2.5	2.5	2.5	2.5
ms	0.5	0.03	0.06	0.06	0.06	0.03

* Atrial and ventricular thresholds at the time of implantation were checked by pacing system analyzer with fixed pulse duration of 0.5 ms. Thresholds at subsequent follow up were checked using pacemaker programmer with fixed amplitude of 2.5V.

positioning of endocardial electrode may be difficult[3] and sometimes epicardial pacing is necessary.[4] In about 80-90% of cases, the right SVC persists providing a alternative route. However, in most circumstances, the diagnosis of persistent left SVC was made only after venous puncture or cephalic vein cut down. Successful implantation of dual chamber pacemaker in patient with persistent left SVC using left-sided approach has been reported.[5-7] Our case demonstrated that by the use of appropriately curved stylet and skillful manipulation, dual chamber pacemaker can be implanted using passive fixation ventricular lead and active fixation atrial lead with satisfactory long term result. Persistent left SVC can be diagnosed by echocardiography. In parasternal long and apical four chamber view with tilting of the probe posteriorly, the dilated coronary sinus can be noted. With injection of agitated saline contrast through the left upper limb, bubbles can be seen going through the dilated coronary sinus to the right atrium. However, in view of the low incidence of persistent left SVC in the population, echocardiogram is not recommended in all patients undergoing pacemaker implantation unless there is other indication. If the diagnosis is made before the procedure, using right-sided approach for leads insertion may be a better option because it is technically easier and the procedure time can be shortened. Both active and passive fixation leads have been used for right ventricular pacing in case reports in the literature. The risk of lead dislodgement is low and the long-term result is similar. On the contrary, active fixation is usually required for the right atrial pacing (most of the time on the right atrial free wall) in most cases because of unfavourable anatomy. There is also one case report of pacing the left ventricle in a patient with left SVC through the left ventricular branch of coronary sinus.[8] This is not a common practice and the long-term result is not certain.

References

1. Lenox CC, Zuberbuhler JR, Park SC, et al. Absent right superior vena cava with persistent left superior vena cava: implications and management. Am J Cardiol 1980;45:117-22.
2. Kjellberg RS, Mannheimer E, Rudhe U, et al. Diagnosis of Congenital Heart Disease. The Year Book Publishers Inc. 1955, p.4.
3. Dosios T, Gorgogiannis D, Sakorafas K, et al. Persistent left superior vena cava: a problem in the transvenous pacing of the heart. Pacing Clin Electrophysiol 1991;14:389-90.
4. Camm AJ, Dymond D, Spurrell RA. Sinus node dysfunction associated with the absenceof right superior vena cava. Br Heart J 1979;41:504-7.
5. Dirix LY, Kersschot IE, Fierens H, et al. Implantation of a dual chamber pacemaker in a patient with persistent left superior vena cava. Pacing Clin Electrophysiol 1988;11:343-5.
6. Roberts DH, Bellamy CM, Ramsdale DR. Implantation of a dual chamber pacemaker in a patient with persistent left superior vena cava. Int J Cardiol 1992;36:242-3.
7. Antonelli D, Rosenfeld T. Implantation of dual chamber pacemaker in a patient with persistent left superior vena cava. Pacing Clin Electrophysiol 1997;20:1737-8.
8. Birnie D, Tang AS. Permanent pacing from a left ventricular vein in a patient with persistent left and absent right superior vena cava. Pacing Clin Electrophysiol 2000;23:2135-7.