

# Constrictive Pericarditis

Dr. Tsui Kin Lam  
Pamela Youde Nethersole Eastern Hospital

Hong Kong Core Cardiology Certificate Course (Module 3)  
7 April 2019

1

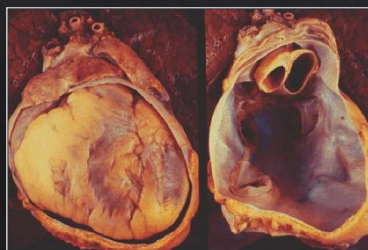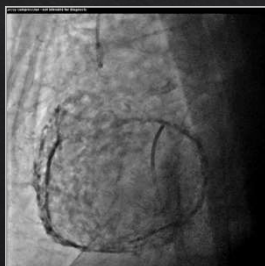## Constrictive Pericarditis

It is like something delicious

Hard Outside



Soft Inside



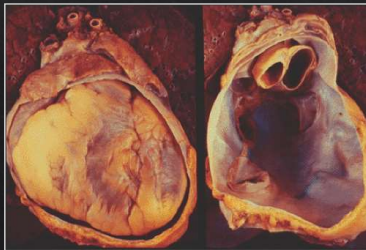
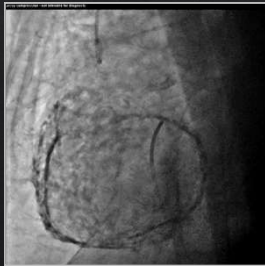2

## Constrictive Pericarditis

Hard Outside



Soft Inside



Idiopathic  
Tuberculosis  
Prior cardiac surgery  
Chest irradiation

Prior acute pericarditis  
Rheumatologic disease  
Malignancy  
Trauma

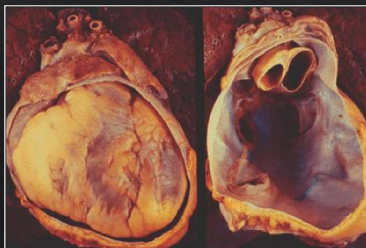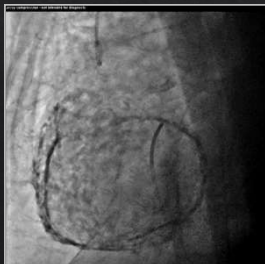3

## Constrictive Pericarditis

Hard Outside



Soft Inside



4

## Constrictive Pericarditis

Normal Systole

Abnormal Diastole

- Normal/rapid **Early** Diastole
- Abnormal **Mid-Late** Diastole



Clinical Effects:

- Diastolic Heart Failure
- Right Heart Failure

5

## Constrictive Pericarditis

Making Correct Diagnosis Is Essential  
> Pericardectomy Is Curative

Presentations:

- SOB on Exertion
- Oedema
- Abdominal Distension  
(Liver Congestion / Ascites)
- Pleural Effusion
- Fatigue
- Atrial Arrhythmia



6



## Constrictive Pericarditis

But how To Make The Diagnosis ?

### Presentations:

- SOB on Exertion
- Oedema
- Abdominal Distension  
(Liver Congestion / Ascites)
- Pleural Effusion
- Fatigue
- Atrial Arrhythmia



7

## Constrictive Pericarditis

But how To Make The Diagnosis ?

First: Be Suspicious



### Unexplained

- R heart failure
- Pleural effusion

### Predisposing conditions

- Tuberculosis
- Prior cardiac surgery
- Chest irradiation

8

## Constrictive Pericarditis

How To Make The Diagnosis ?

First: Be Suspicious



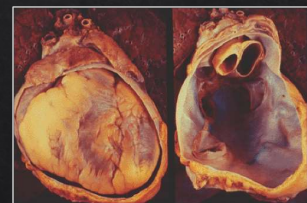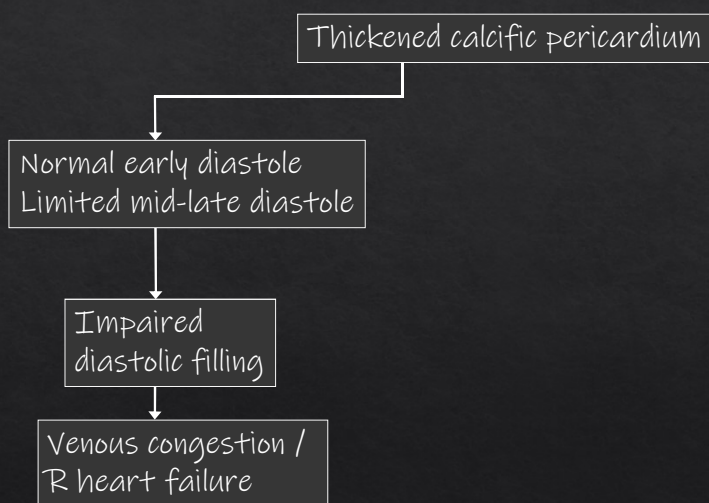
Then

Think of something Yummy

Look for something fancy

9

## Constrictive Pericarditis From Pathophysiology to Diagnosis



10

### Constrictive Pericarditis From Pathophysiology to Diagnosis


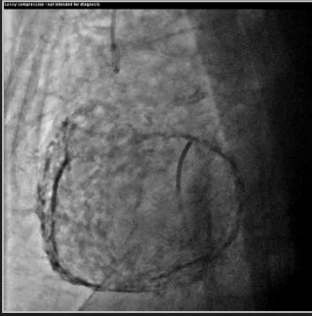
Thickened calcific pericardium

Normal early diastole  
Limited mid-late diastole

Impaired diastolic filling

Venous congestion /  
R heart failure

CXR: Pericardial Calcification

11

### Constrictive Pericarditis From Pathophysiology to Diagnosis



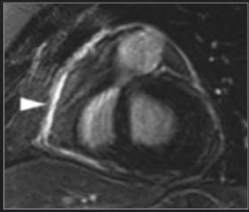
Thickened calcific pericardium

Normal early diastole  
Limited mid-late diastole

Impaired diastolic filling

Venous congestion /  
R heart failure

Echo, CT, MRI...

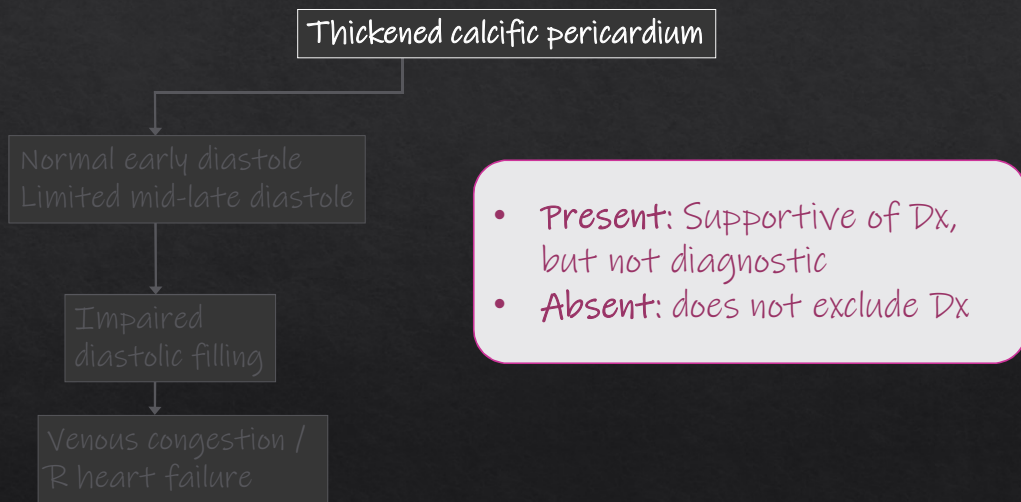




12



## Constrictive Pericarditis

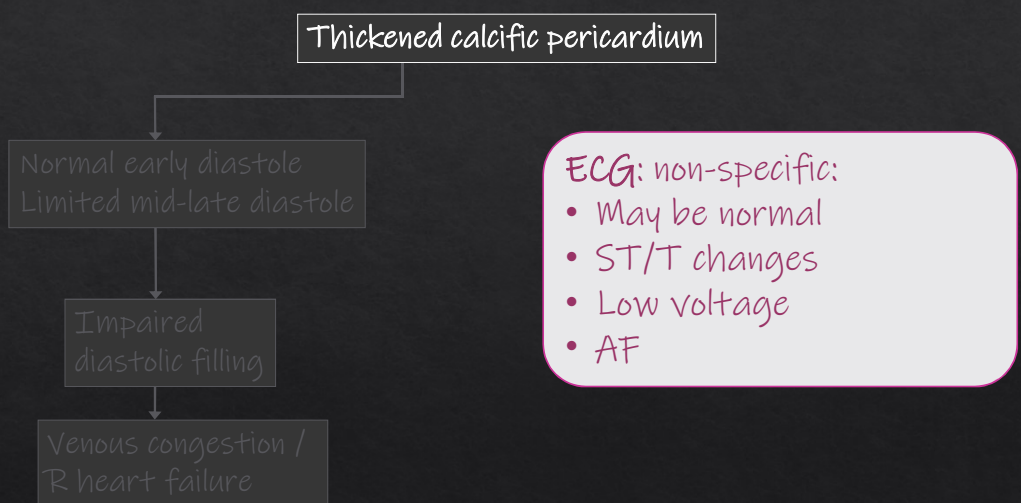
### From Pathophysiology to Diagnosis



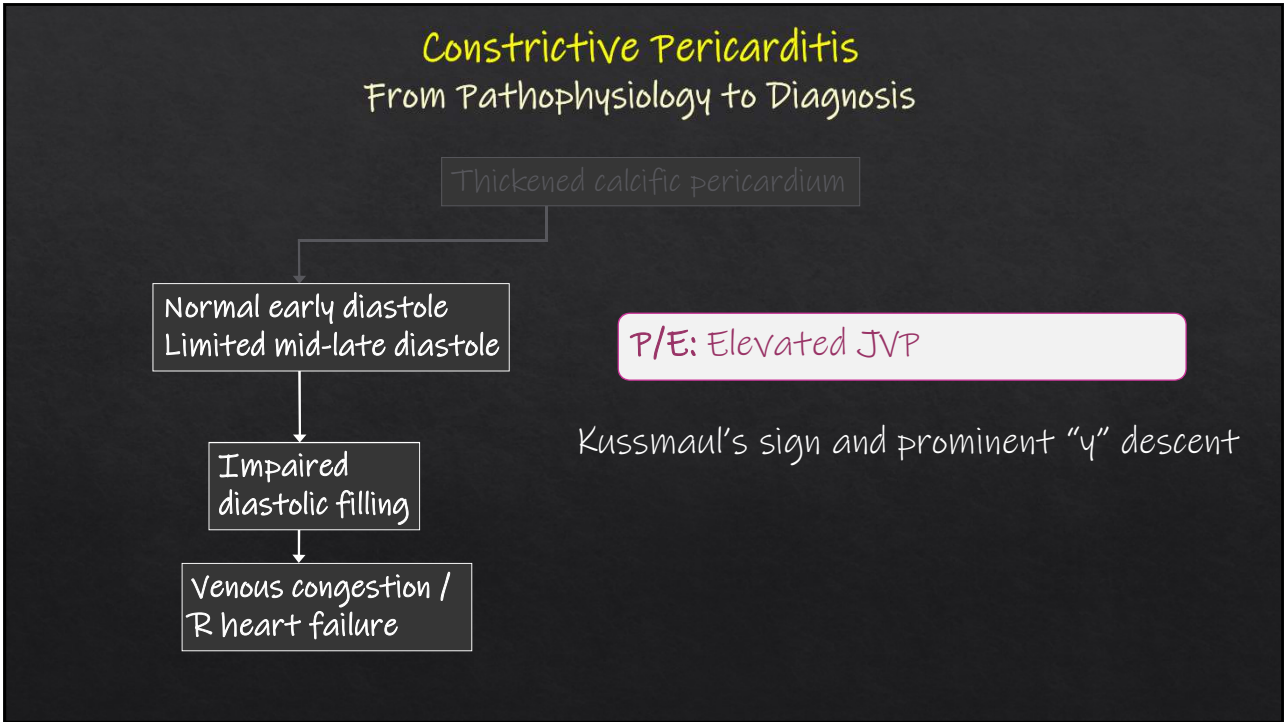
13

## Constrictive Pericarditis

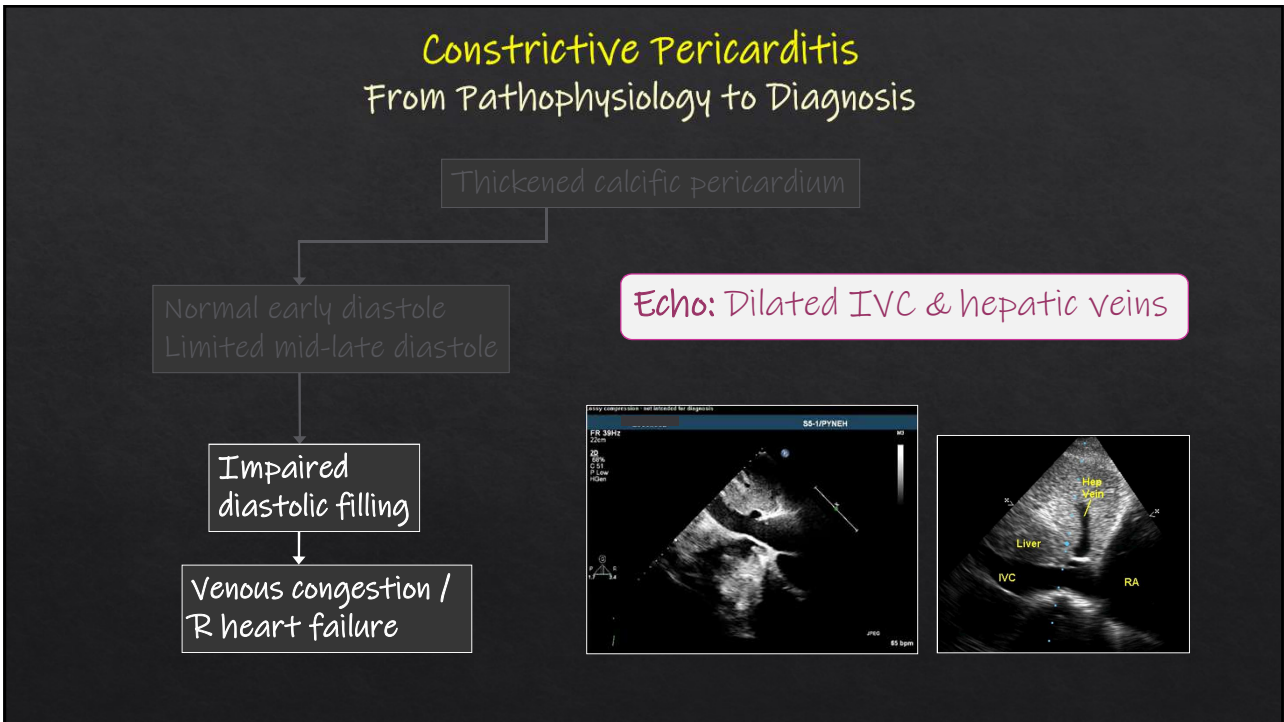
### From Pathophysiology to Diagnosis



14



15

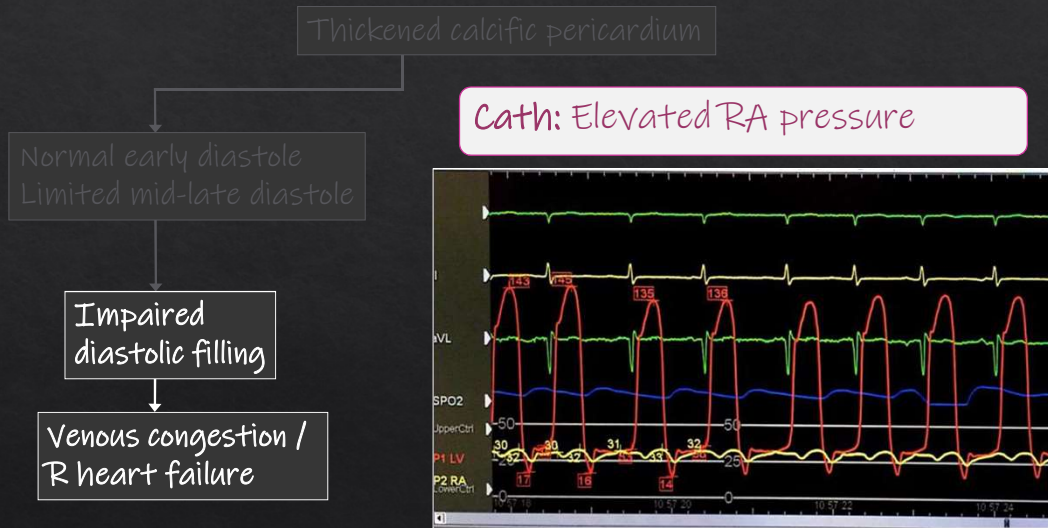


16



## Constrictive Pericarditis

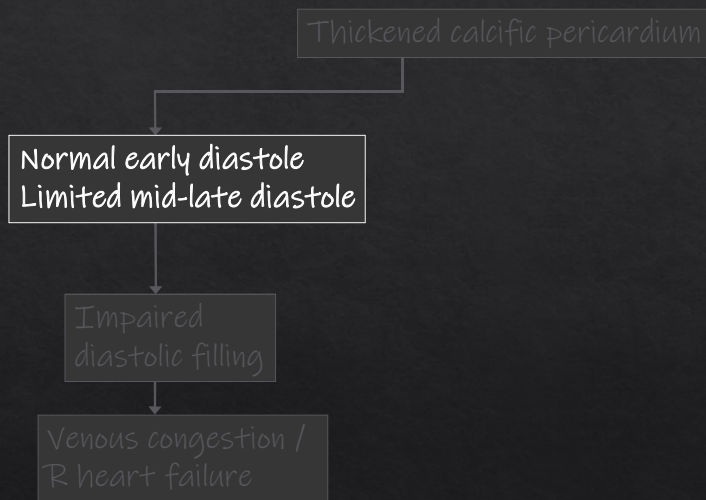
### From Pathophysiology to Diagnosis



17

## Constrictive Pericarditis

### From Pathophysiology to Diagnosis



18

### Constrictive Pericarditis

#### From Pathophysiology to Diagnosis

Thicke

Early diastolic flattening of LVPW

Normal early diastole  
Limited mid-late diastole

↓

Impaired diastolic filling

↓

Venous congestion /  
R heart failure

19

### Constrictive Pericarditis

#### From Pathophysiology to Diagnosis

Thickened calcific pericardium

Normal early diastole  
Limited mid-late diastole

↓

Impaired diastolic filling

↓

Venous congestion /  
R heart failure

**Cardiac Cath:**

- RA: Prominent "y" descent
- Dip-and-Plateau or Square Root Sign
- Equalization of diastolic pressures of 4 chambers

20

### Constrictive Pericarditis

#### From Pathophysiology to Diagnosis

Thickened calcific pericardium

Normal early diastole  
Limited mid-late diastole

↓

Impaired diastolic filling

↓

Venous congestion /  
R heart failure

RA Pressure: Prominent y descent

21

### Constrictive Pericarditis

#### From Pathophysiology to Diagnosis

Thickened calcific pericardium

Normal early diastole  
Limited mid-late diastole

↓

Impaired diastolic filling

↓

Venous congestion /  
R heart failure

LV Diastolic Pressure:  
Dip and Plateau (Square Root Sign)

22



### Constrictive Pericarditis

#### From Pathophysiology to Diagnosis

Thickened calcific pericardium

Normal early diastole  
Limited mid-late diastole

Impaired diastolic filling

Venous congestion /  
R heart failure

Equalization of Diastolic Pressures  
LV-RV Pressures

23

### Constrictive Pericarditis

#### From Pathophysiology to Diagnosis

Thickened calcific pericardium

Normal early diastole  
Limited mid-late diastole

Impaired diastolic filling

Venous congestion /  
R heart failure

Equalization of Diastolic Pressures

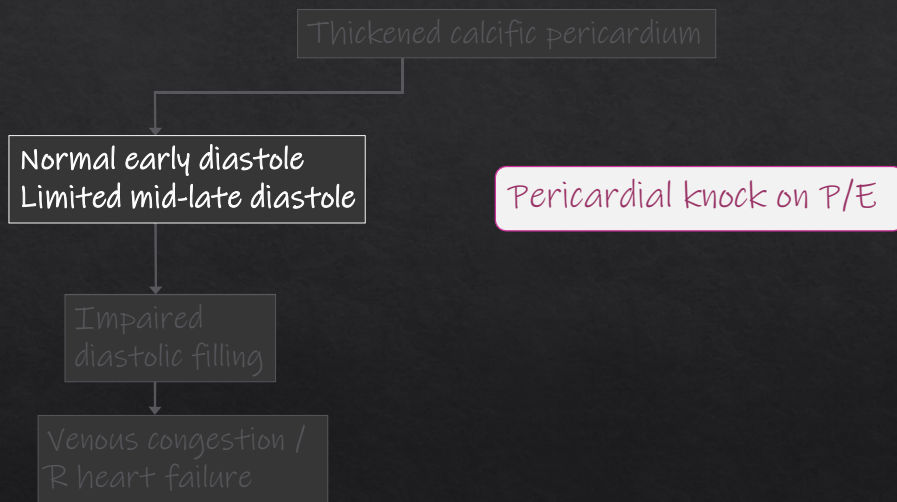
LV-RA Pressures

LV-PCWP Pressures

24

## Constrictive Pericarditis

### From Pathophysiology to Diagnosis



25

## Constrictive Pericarditis

### How To Make The Diagnosis ?

First: Be Suspicious



Then

Think of something Yummy

Look for something fancy

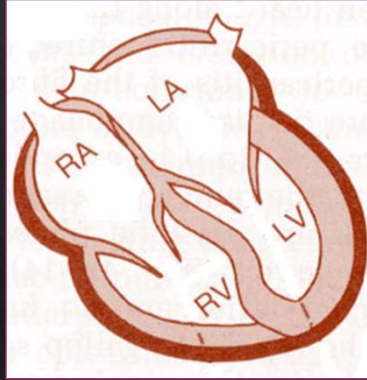
Thinking of fancy relationships  
makes your mind clearer

26

## Constrictive Pericarditis

### The Fancy Relationship of Mr. Right & Ms. Left

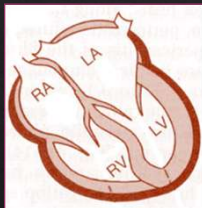
Enhanced  
Ventricular  
Interdependence



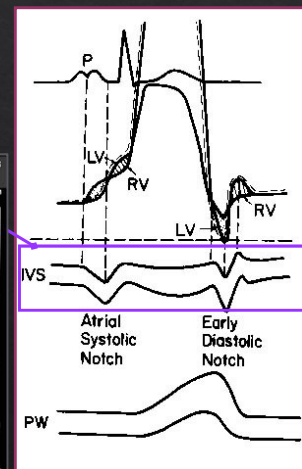
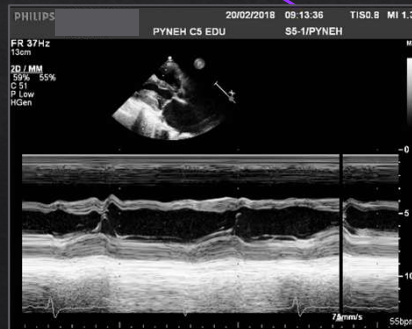
27

## Constrictive Pericarditis

### Enhanced Ventricular Intedependence



Septal bouncing  
On M-Mode or 2D



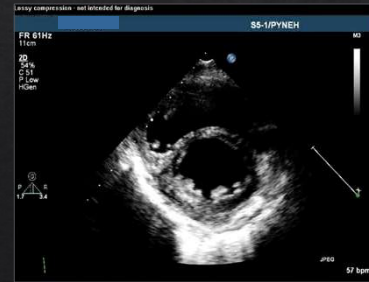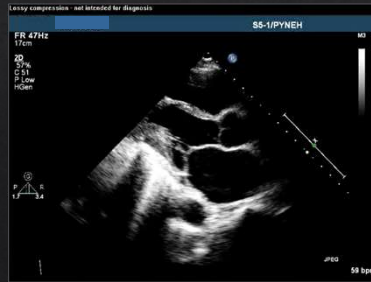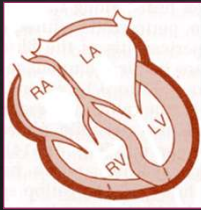
28



# Constrictive Pericarditis

## Enhanced Ventricular Intdependence

Septal bouncing  
On M-Mode or 2D

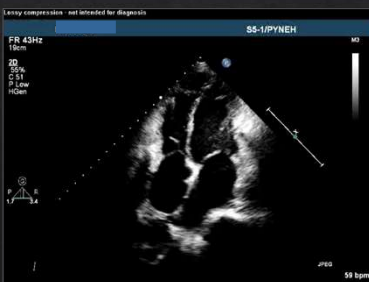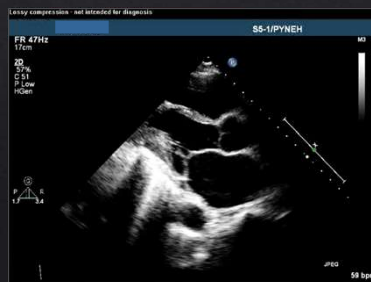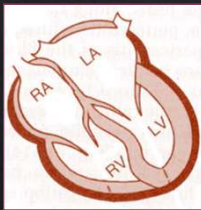


29

# Constrictive Pericarditis

## Enhanced Ventricular Intdependence

Septal bouncing  
On M-Mode or 2D



30

## Constrictive Pericarditis

### The Fancy Relationship of Mr. Heart & Ms. Lung

↓ Air In

Dissociation of intrathoracic and intracardiac pressures

The diagram shows a cross-section of the human chest. The lungs are colored red and the heart is a red heart shape in the center. A yellow arrow labeled 'Air In' points to the trachea. The lungs are filled with a blue branching network representing the bronchial tree. The heart is positioned between the two lungs.

31

## Constrictive Pericarditis

### Dissociation of Intrathoracic and Intracardiac Pressures

Exaggerated respiratory variation in MV/Pulm Vein flow  
 Inspiratory dec in mitral "E" (>25%)

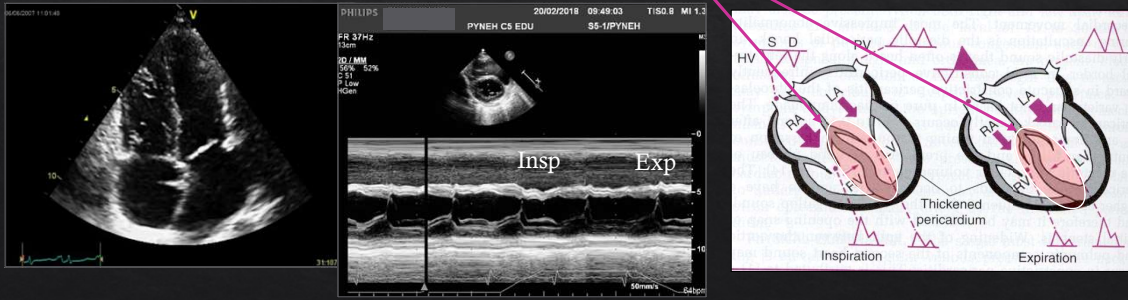
The left side of the slide shows a Philips ultrasound Doppler image. The top part displays technical parameters: PHILIPS, 20/02/2018, 09:31:35, TISO.5, MI 0.6, PYNEH C5 EDU, S5-1PYNEH. The main image shows a color Doppler flow spectrum with a respiratory cycle labeled 'Insp' and 'Exp'. The flow is predominantly negative, indicating flow towards the transducer. The right side of the slide contains two anatomical diagrams of the heart. The left diagram is labeled 'Inspiration' and shows the heart with a thickened pericardium. The right diagram is labeled 'Expiration' and shows the heart with a thickened pericardium. The diagrams illustrate the relationship between the heart and the lungs during these phases.

32

## Constrictive Pericarditis

Dissociation of Intrathoracic and Intracardiac Pressures Together with Enhanced Ventricular Interdependence

Ventricular septal shift to left during inspiration

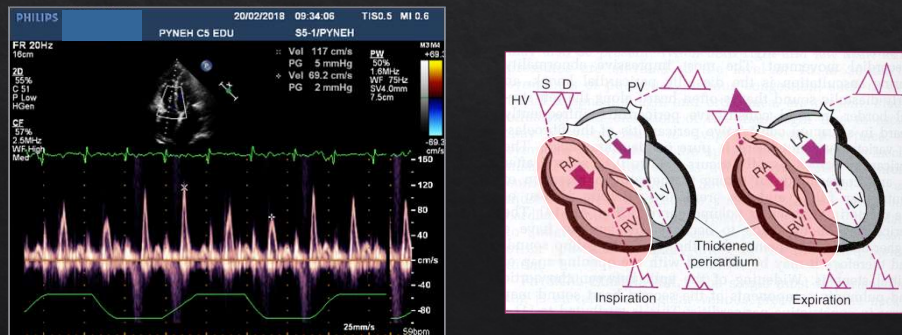


33

## Constrictive Pericarditis

Dissociation of Intrathoracic and Intracardiac Pressures Together with Enhanced Ventricular Interdependence

Exaggerated respiratory variation in TV flow (usu >40% with inspiration)

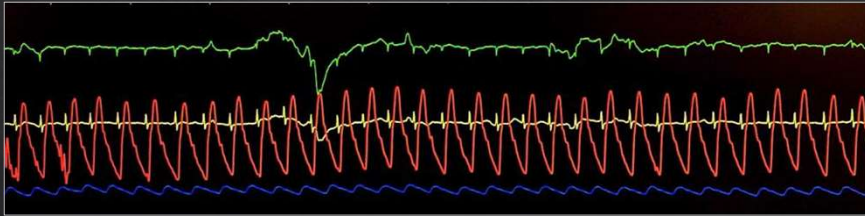


34

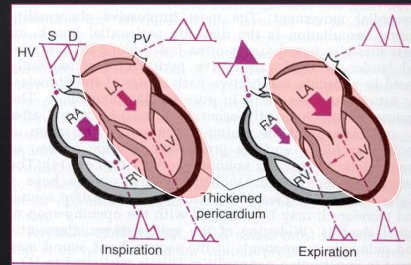


## Constrictive Pericarditis

Dissociation of Intrathoracic and Intracardiac Pressures



Pulsus Paradoxus

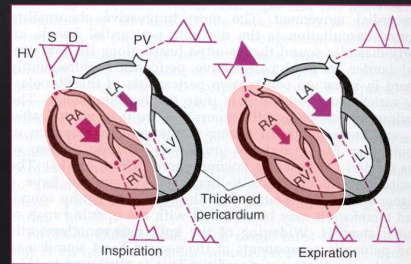
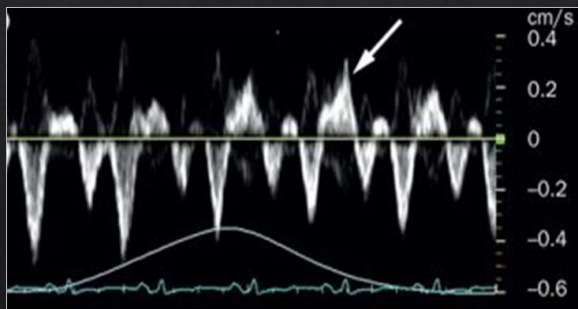


35

## Constrictive Pericarditis

Dissociation of Intrathoracic and Intracardiac Pressures Together with Enhanced Ventricular Interdependence

Hepatic venous flow:  
- Diastolic flow reversal in expiration

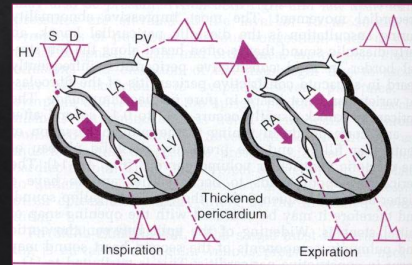


36

## Constrictive Pericarditis

Dissociation of Intrathoracic and Intracardiac Pressures  
Together with Enhanced Ventricular Interdependence

Cardiac Cath

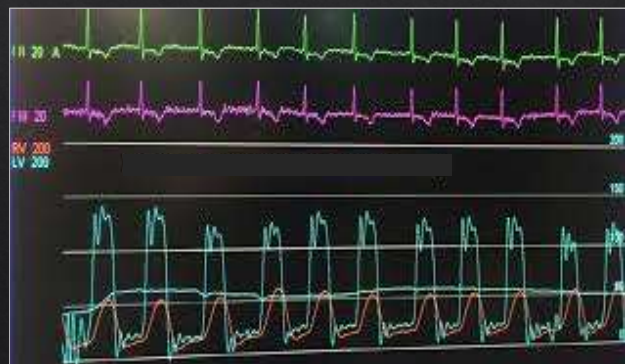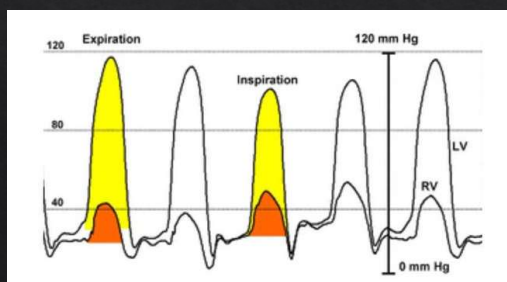


37

## Constrictive Pericarditis

Dissociation of Intrathoracic and Intracardiac Pressures  
Together with Enhanced Ventricular Intedependence

Discordance in LV-RV Pressures  
with Respiration

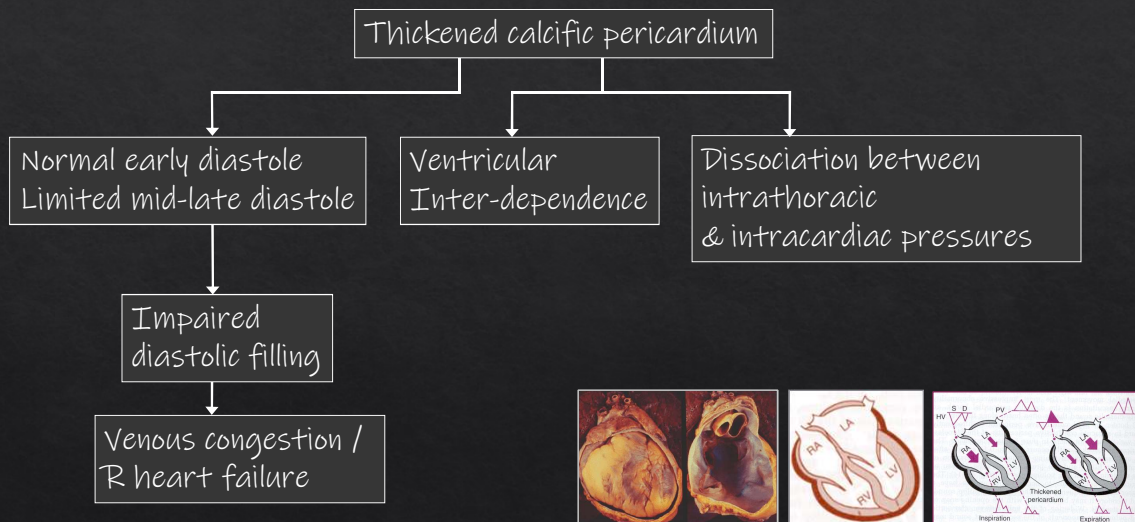


38



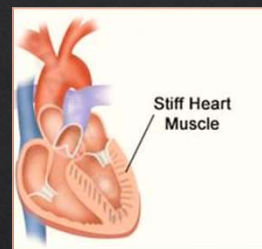
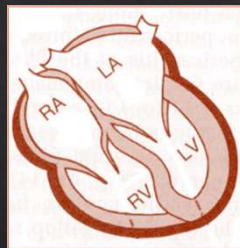
## Constrictive Pericarditis

### From Pathophysiology to Diagnosis



39

## Constrictive Pericarditis Vs Restrictive Cardiomyopathy



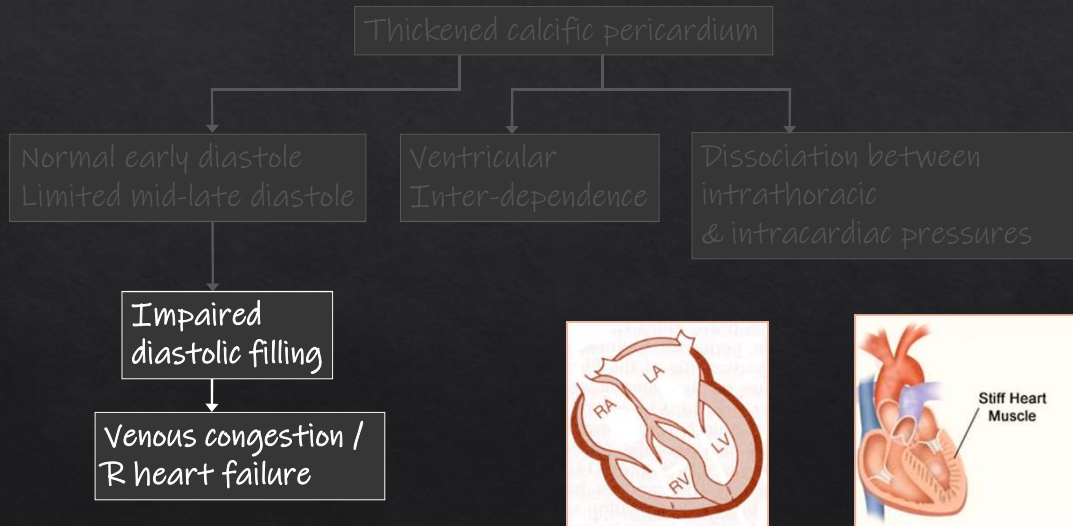
Both are uncommon causes of diastolic heart failure presenting with unexplained venous congestion

Constrictive pericarditis is potentially curable

40

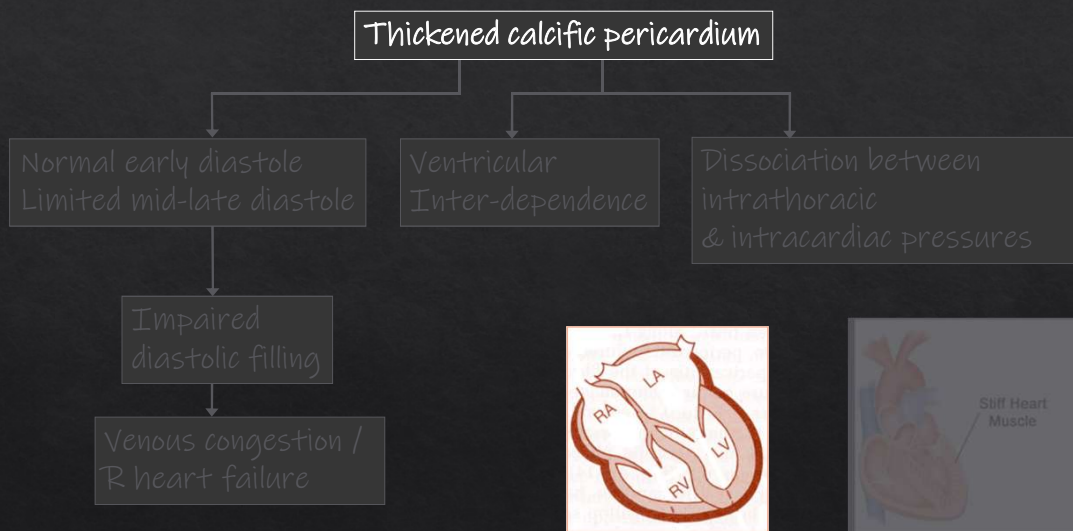


## Constrictive Pericarditis Vs Restrictive Cardiomyopathy



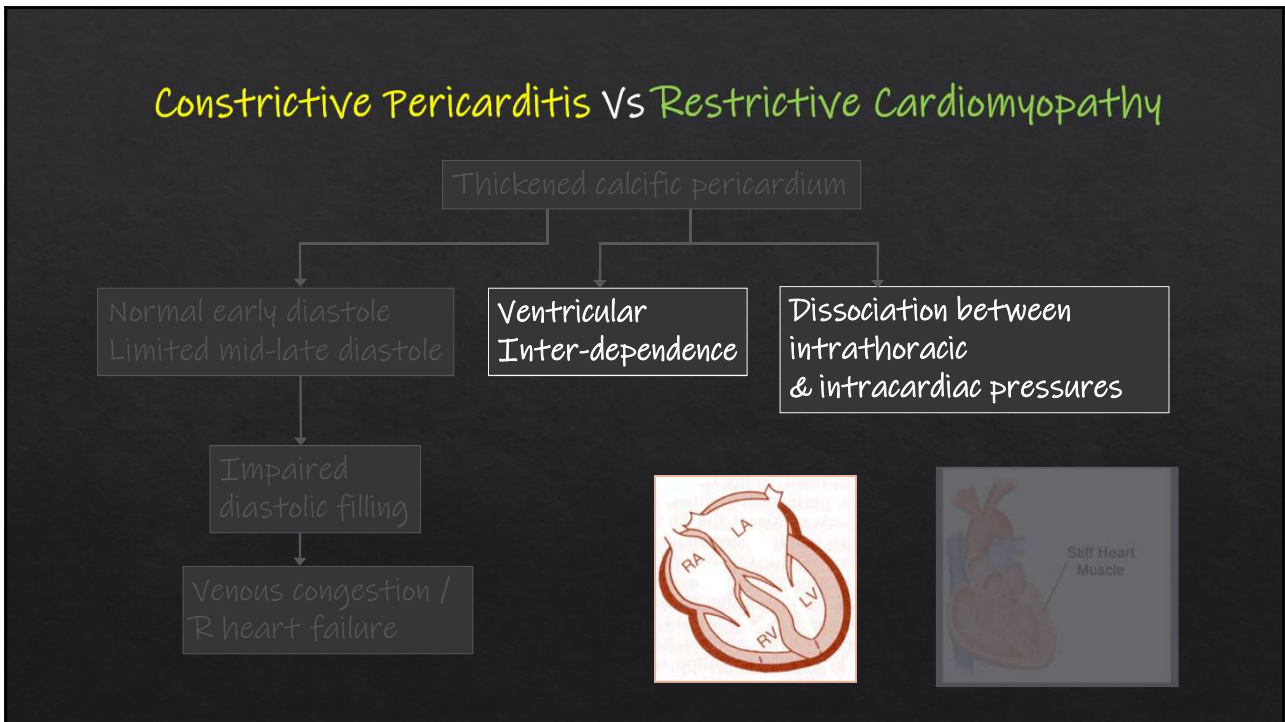
41

## Constrictive Pericarditis Vs Restrictive Cardiomyopathy



42

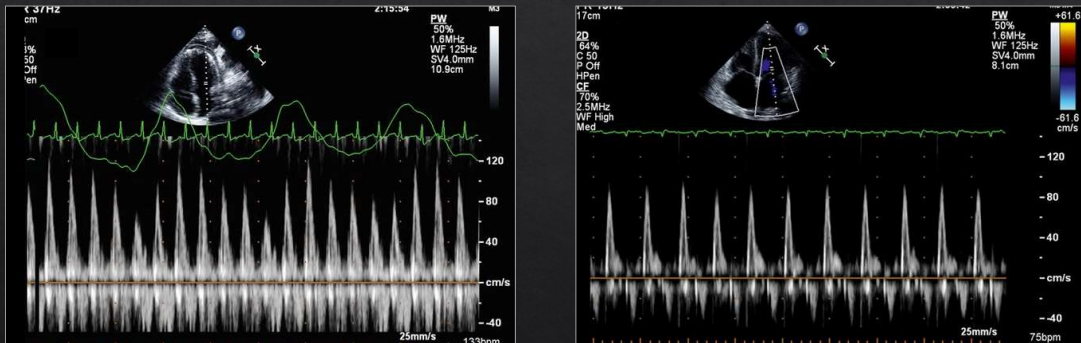
## Constrictive Pericarditis Vs Restrictive Cardiomyopathy



43

## Constrictive Pericarditis Vs Restrictive Cardiomyopathy

Mitral Flow

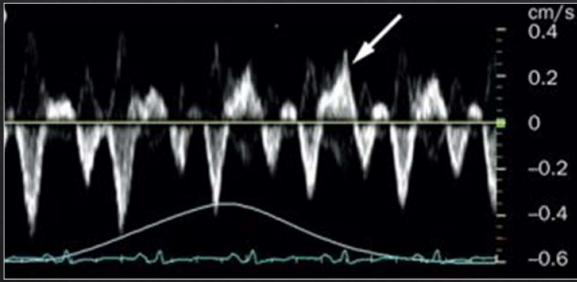


44

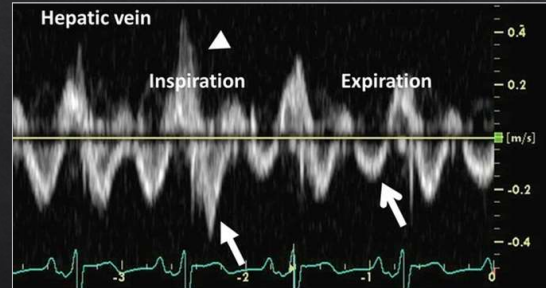
### Constrictive Pericarditis Vs Restrictive Cardiomyopathy



Hepatic Venous Flow



Predominantly on Expiration



Predominantly on Inspiration

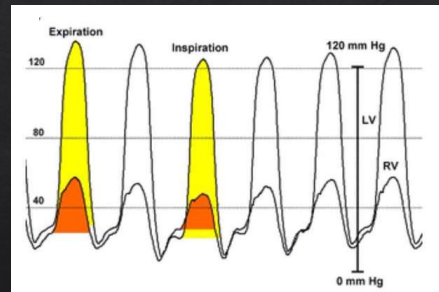
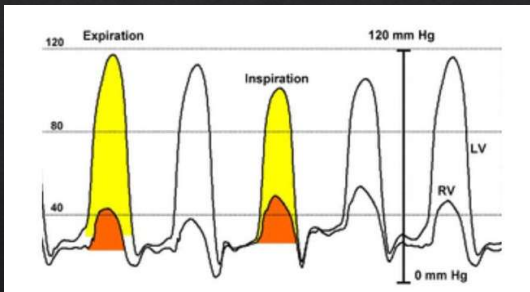
45

### Constrictive Pericarditis Vs Restrictive Cardiomyopathy



Discordance in LV-RV Pressures

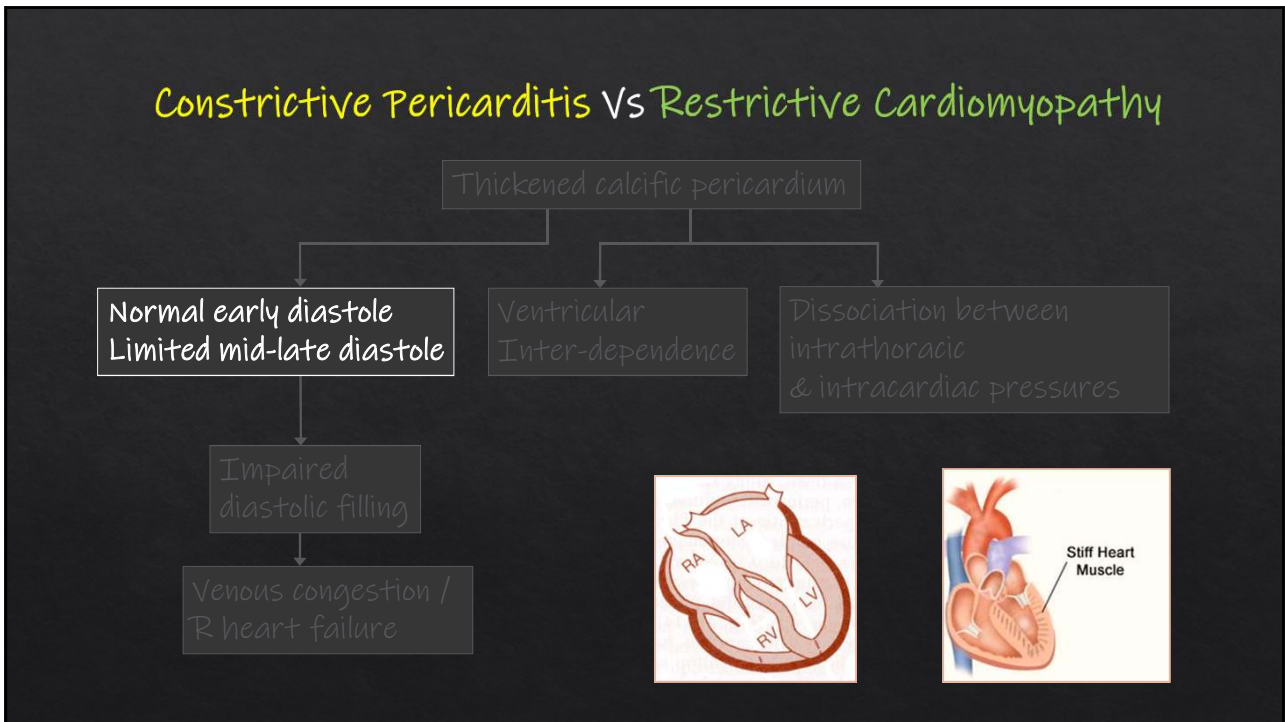
Concordance in LV-RV Pressures



46

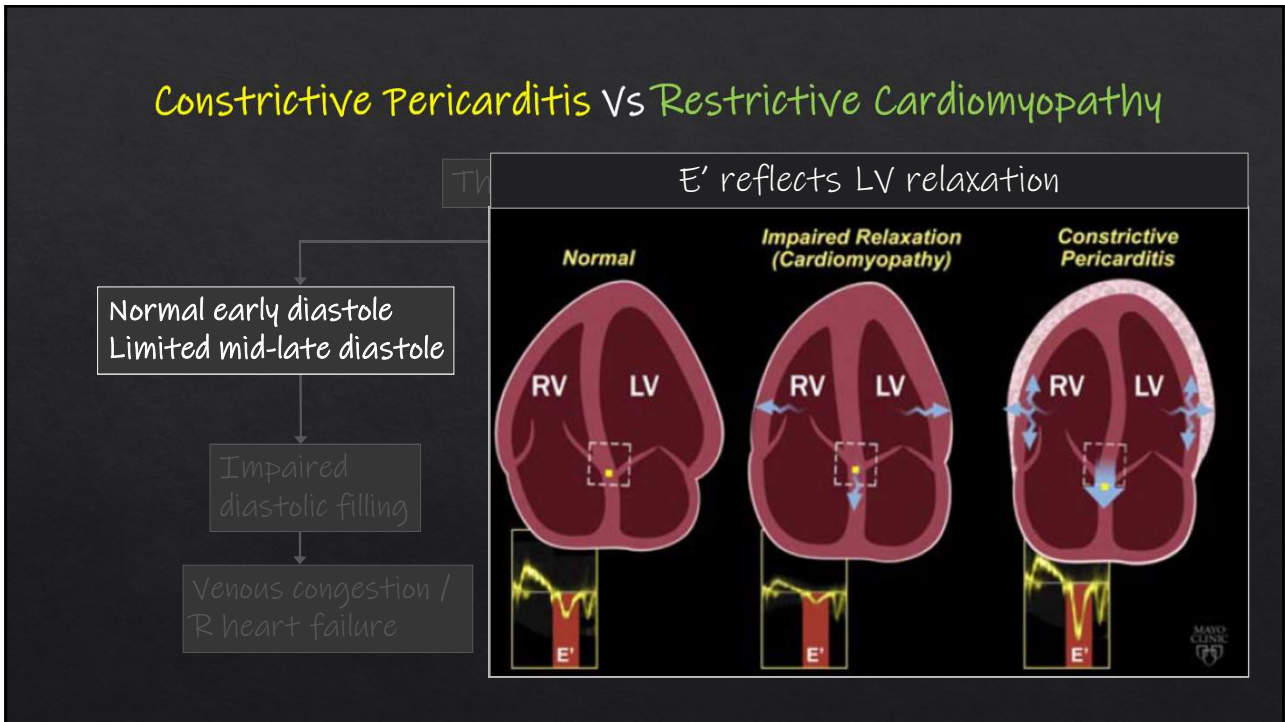


## Constrictive Pericarditis Vs Restrictive Cardiomyopathy



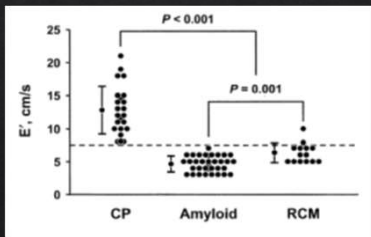
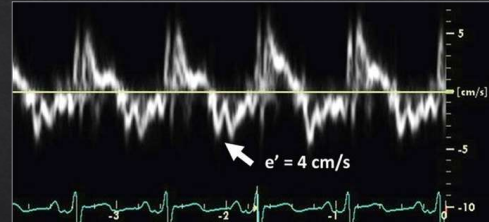
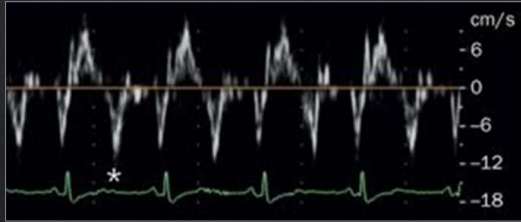
47

## Constrictive Pericarditis Vs Restrictive Cardiomyopathy



48

## Constrictive Pericarditis Vs Restrictive Cardiomyopathy



Medial E'  $\geq 8$  cm/s suggests constrictive pericarditis

Ha JW, et al. AJC 2004

49

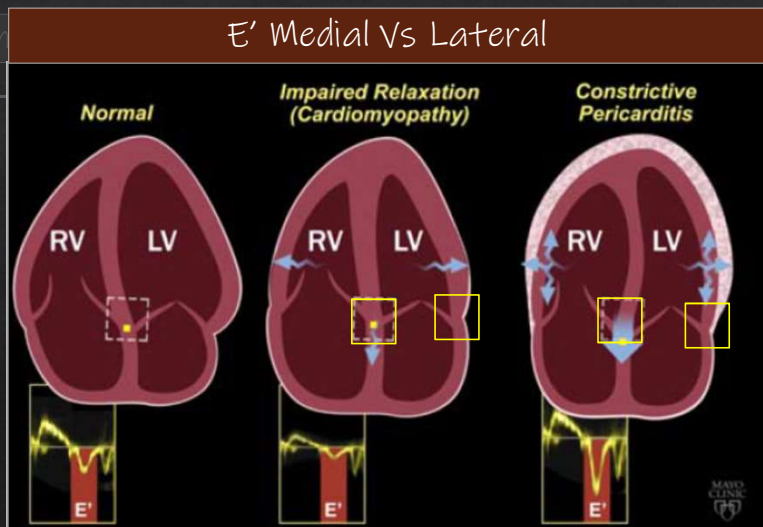
## Constrictive Pericarditis Vs Restrictive Cardiomyopathy

### E' Medial Vs Lateral

Normal early diastole  
Limited mid-late diastole

Impaired diastolic filling

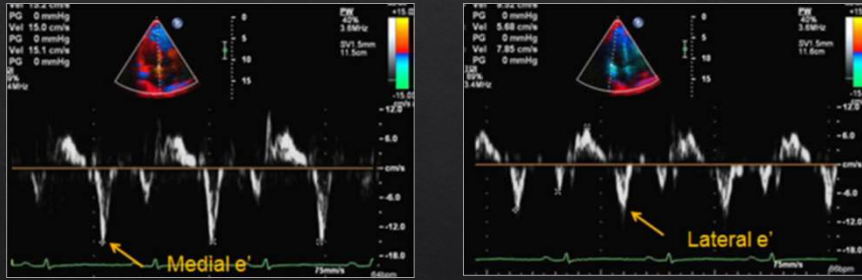
Venous congestion / R heart failure



50

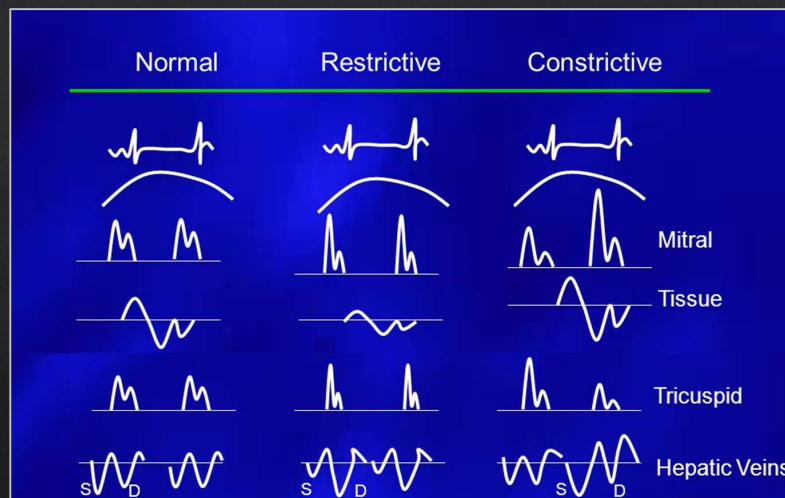
## Constrictive Pericarditis Vs Restrictive Cardiomyopathy

Annulus reversus: Medial E' > Lateral E'



51

## Constrictive Pericarditis Vs Restrictive Cardiomyopathy



Adapted from Hoit B, Circulation 2002

52



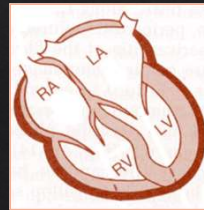
## Constrictive Pericarditis

Normal early diastole  
Limited mid-late diastole

Impaired  
diastolic filling

Venous congestion /  
R heart failure

- RA: Prominent "y" descent
- Dip-and-Plateau or Square Root Sign
- Equalization of diastolic pressures of 4 chambers



53

## Constrictive Pericarditis Vs Restrictive Cardiomyopathy

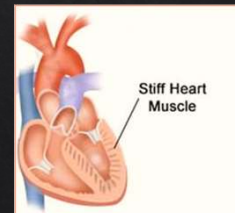
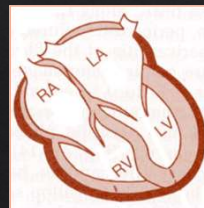
Normal early diastole  
Limited mid-late diastole

Impaired  
diastolic filling

Venous congestion /  
R heart failure

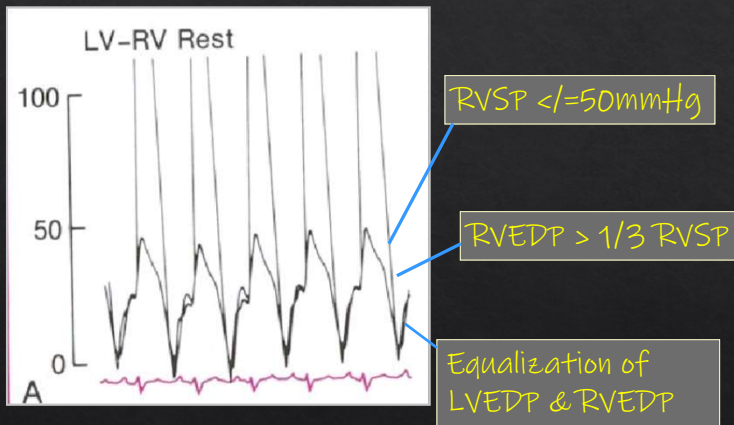
Overlapping features on Cardiac Cath:

- RA: Prominent "y" descent
- Dip-and-Plateau or Square Root Sign
- Equalization of diastolic pressures of 4 chambers



54

## Constrictive Pericarditis Vs Restrictive Cardiomyopathy



55

## Constrictive Pericarditis Vs Restrictive Cardiomyopathy

When doubt persists...

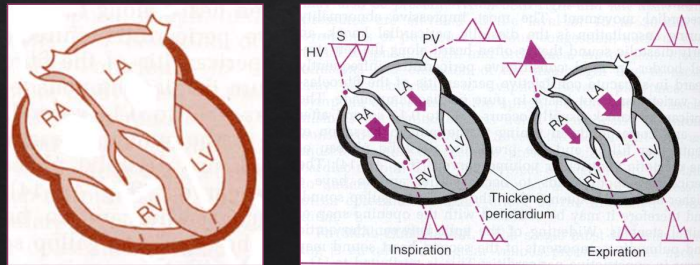
Endomyocardial biopsy

Surgical Exploration

56

## Summary

### When Suspicious of Constrictive Pericarditis...



57

### When Suspicious of Constrictive Pericarditis...

◆ Look in **pulse** something you seldom did

Pulsus paradoxus

◆ Look in **JVP** something you easily missed

Kussmaul's sign  
Prominent y descent

◆ Look in **ECG** something not so drastic

ST/T changes  
Low voltage

◆ Look in **CXR** something not specific

Pericardial calcification

58



## When Suspicious of Constrictive Pericarditis...

On Echo, look for...

- ◊ **Septal bouncing** that may save your day
- ◊ A deep **breath in** pushes the **septum** away (toward LV)
- ◊ **Pericardium** may look thick and bright
- ◊ **Diastolic flattening** (of LVPW) is a common sight

59

## When Suspicious of Constrictive Pericarditis...

On Echo, look for...

- ◊ **Mitral flow** drops with breathing ... inspiratory
- ◊ **Tricuspid flow** increases on the contrary
- ◊ **Medial E'** commonly greater than eight
- ◊ **Lateral E'** is a little bit sick

60

## When Suspicious of Constrictive Pericarditis...

On Echo, look for...

- ◊ Inspiration does not collapse the IVC
- ◊ Expiration increases diastolic flow reversal in hepatic vein, you see?

61

## When Suspicious of Constrictive Pericarditis...

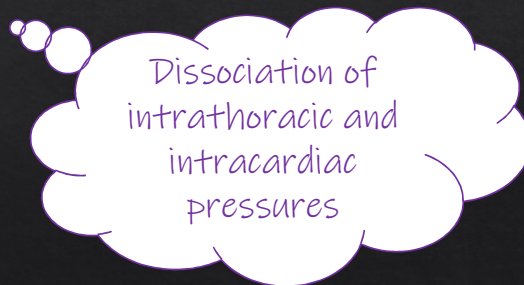
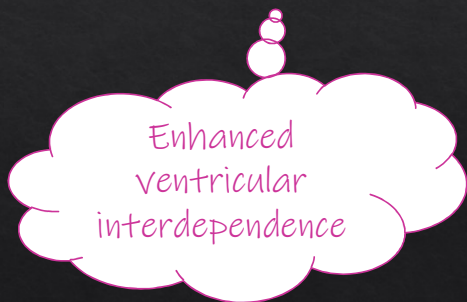On Cardiac Cath, look for...

- ◊ RA pressure raised with rapid descent "y"
- ◊ Dip-and-plateau, also called "square-root sign"
- ◊ Diastolic pressures in all chambers raised and equal
- ◊ Discordance in LV-RV pressures is something special

62

## When Suspicious of Constrictive Pericarditis...

- ◆ Think of something yummy
- ◆ Look for something fancy



63

Thank you!



64