An Anticoagulant Therapy for Primary Left Upper-Extremity Deep Vein Thrombosis (Paget-Schroetter Syndrome): A Case Report

TETSUO ICHINOSE, HIROSHIGE YUU, YUKI YOKOMATSU, MIKI YAMASE, YASUNOBU KAWANO, HAKUOH KONISHI, KOSEI TANIMOTO, TETSUYA OIGAWA, YOUICHI KATOH, YUJI NAKAZATO

From Department of Cardiology, Juntendo University Urayasu Hospital, Japan

ICHINOSE ET AL.: ***An Anticoagulant Therapy for Primary Left Upper-Extremity Deep Vein Thrombosis (Paget-Schrotter Syndrome): A Case Report.*** *A 24-year-old man was presented to our hospital with edema on the left upper-extremity. Left upper-extremity venography demonstrated obstruction of the left axillary to subclavian vein and poor ipsilateral collateral superficial vein. Heparin therapy was started, and subsequently replaced with warfarin therapy. The venography showed antegrade axillary and subclavian venous stream with residual stenosis and good collateral superficial vein after 6 months. Although the precise trigger of thrombosis was undetermined in our patient, Paget-Schroetter syndrome was considered as an appropriate diagnosis. This disorder is always kept in mind if a young healthy man has the upper-extremity edema without obvious triggers. (J HK Coll Cardiol 2009;17:27-31)*

Axillary vein, effort deep vein thrombosis, primary deep vein thrombosis, subclavian vein, upper-extremity

摘要

一名２４歲男性因左上肢水腫與我院就診。左上肢靜脈造影顯示鎖骨下靜脈至左腋靜脈阻塞，同一側枝淺表靜脈顯示不清。開始給予肝素療法，其後以華法林替代。６　周後靜脈造影顯示腋靜脈通暢，鎖骨下靜脈部分狹窄，側枝淺表靜脈顯示良好。儘管該患者血栓形成的確切誘發因素尚未明確，但Paget-Schroetter綜合症的診斷是恰當的。年青健康男性無明顯誘因下出現上肢浮腫時需警惕該診斷。

關鍵詞：腋靜脈　嚴重深靜脈血栓　原發性深靜脈血栓　鎖骨下靜脈　上肢

Introduction

Upper-extremity deep vein thrombosis (UEDVT) accounts for about 1-2% of all deep vein thrombosis (DVT).[1] Although secondary UEDVT has increased recently as a use of central venous catheter, primary UEDVT, or effort thrombosis, so called Paget-Schroetter syndrome is a rare disease.[2] We report a case of Paget-Schroetter syndrome, successfully treated with an anticoagulation therapy without any resulting complications.

Case Report

A 24-year-old man was presented to our hospital with an episode of left upper-extremity edema 7 days earlier. He had no history of illness, such as trauma, malignant disease, coagulopathy, or thrombosis, no medical care history of central venous catheter insertion and no family history of coagulopathy. He used to be a right-handed baseball player in high school and

Address for reprints: Dr. Tetsuo Ichinose
Department of Cardiology, Juntendo University Urayasu Hospital, 2-1-1 Tomioka, Urayasu City, Chiba, 279-0021, Japan

Email: tichinose@juntendo-urayasu.jp

Received March 9, 2009; revision accepted March 17, 2009

currently works as a magazine editor. His height and body weight were 173 cm and 60 kg and has a medium build. On admission, physical examination turned up nothing out of the ordinary except for a left upper limb edema and cyanosis. Electrocardiogram showed a regular sinus rhythm with a heart rate of 67 beats per min without any signs of right heart overloading. The serum levels of anti-cardiolipin antibody, protein C, protein S, anti-thrombin III, lupus anticoagulant, tumor marker and collagen disease marker were each within the normal ranges. The D-dimer level was positive with a measurement of 2.52 μg/mL. Contrast-enhanced chest computed tomography (CT) and left upper extremity venography showed complete thrombotic obstruction in the left axillary to brachiocephalic vein and poor ipsilataral collateral superficial vein without any findings of pulmonary thromboembolism (PTE) (Figures 1A & 1B). One week had already passed since the occurrence; therefore, intravenous unfractional heparin sodium therapy without thrombolysis was performed. The heparin was titrated as achieving the activated partial thromboplastin time (APTT) of 1.5 to 2.0 times compared with the control. Then, intravenous heparin was replaced by oral anticoagulation therapy with warfarin potassium at target prothrombin time international ratio (PT-INR) of 2.0 to 3.0. After the 14th day of the hospitalization, the left upper-extremity swelling and cyanosis were improved. The left upper-extremity venography showed a complete obstruction of axillary vein and stenotic lesion in the left subclavian vein, and good collaterals via the ipsilateral shoulder to neck superficial vein. On the 15th day he was discharged. Six months after the onset, left upper-extremity venography demonstrated antegrade perfusion with residual stenosis of the left axillary and subclavian vein, and good collaterals via the ipsilateral chest wall and cervical superficial vein (Figure 1C). Since then he has been followed with anticoagulation therapy in our clinic without any findings of recurrence for 6 months.

Discussion

Primary upper-extremity deep vein thrombosis (UEDVT), effort thrombosis so-called Paget-Schroetter syndrome or idiopathic UEDVT is a rare disease. The incidence is less than 2 per 100,000 persons per year.[2] It has been reported to occur usually in young healthy persons with dominant upper-extremity from repetitive strenuous arm movement, such as abduction.[1,2] Martinelli I. and colleagues reported 115 patients who suffered primary UEDVT. Strenuous efforts were recorded in 29 patients. Fifteen persons had related effort (which 8 were weightlifting, 3 rowing, 2 tennis and 2 volleyball), and 14 were unusual strenuous arm movement (7 were lifting, 4 were prolonged-shoulders extension, 3 were repeated abduction).[3] Other literatures have reported this syndrome in athletes such as golfers, wrestlers, football players and cheerleaders, as well as in painters and beauticians with a history of repetitive overhead arm motions.[4] The number of mechanisms were speculated as follows. The repeated extrinsic mechanical compression of costclavicular space may cause microtrauma of the subclavian vein intima, which leads to the local activation of coagulation cascade and thrombosis. Second, repetitive arm motion may contribute to anatomical stenosis of the costclavicular space through hypertrophy of the subclavian muscle and anterior scalene muscle. Third, external compression such as cervical ribs, fibromuscular band and callus from old clavicular fracture may be caused.[1,2,4] In this case, there was no history of repetitive arm motion, athletics, or a dominant arm. Afterward, he told us that he had the habit of resting his chin on his left hand during deskwork for 2-3 hours. So this behavior of semi-lateral abduction may have contributed to this syndrome.

From 2000 to 2008, 49 cases of UEDVT had been reported in Japan. In our precise reviews, 46 cases suffered idiopathic deep vein thrombosis and 3 cases were secondary UEDVT (lung cancer, antiphospholipid antibody positive and complication of central venous catheter). UEDVT occurs more often in the right arm (R/L = 26/18). Dominant arm thrombosis was observed in 7 out of 10 patients Repetitive overhead arm movement such as baseball and soft ball player (4), football player (1), badminton player (2), Kendo player (1), and dauber (1) were 9 cases and carrying burden on a shoulder such as scaffold constructor were 6 cases. Repetitive lateral abduction arm movement under head such as golf, push-up exercise and hockey player were

3 cases. Keeping arm overhead position hand such as shampoo (2) and lying down using arm to prop up his head (3) were 5 cases. There were no reports that were the habits of resting his chin on his left hand. Therefore, this condition should be included as a triggering posture causing Paget-Schroetter syndrome (Table 1).

He did not have any findings of predisposing thrombotic factors. However idiopathic deep vein thrombosis may be a risk factor of occult cancer.[5] In 343 patients with DVT, 305 had lower extremity DVT (LEDVT) and 38 exhibited upper. The UEDVT group had 9 (23.7%) with diagnosis of cancer during 1 year follow up (most commonly lung cancer and lymphomas)

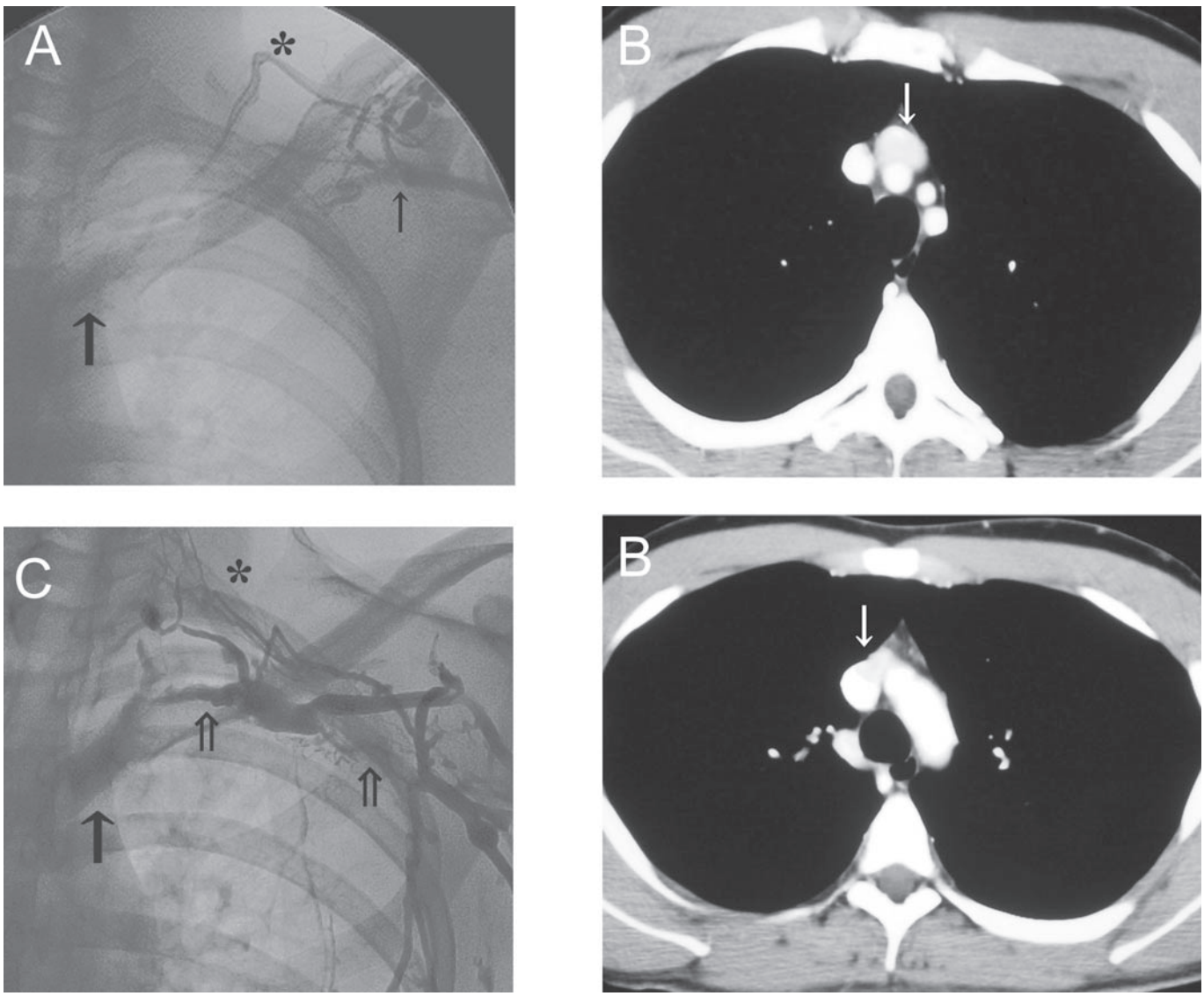

Figure 1. (A) *Initial left upper-extremity venography showed complete obstruction of the left axillary to subclavian vein (narrow arrow) and poor collaterals of ipsilataral collateral superficial vein (asterisk) to supravena cava (bold arrow).* **(B)** *Contrast-enhanced chest computed tomography on admission showed a complete obstruction of the left brachiocephalic to subclavian vein (arrow).* **(C)** *The left upper-extremity venography after 6 months demonstrated the residual stenosis of the axillary and left subclavian vein (double arrow) and good collaterals via the ipsilateral chest wall and neck superficial vein (asterisk) to brachiocephalic vein (bold arrow).*

Table 1. Paget-Schroetter syndrome in Japanese

Total cases			49 (idiopathic 46)
Reference year			2000~2008
Age (year)			39.8±16.1*(16~77)
Male/female			37/9 (N/A 3)
Right/left			26/18 (N/A 5)
Location	BRV~AXV		1
	BRV~SCV		2
	BRV~BRCV		1
	AXV~SCV		8
	SCV		24
	SCV~BRCV		2
	N/A		11
Treatment ~Initiate			
	Anticoagulation		34 (H1, H+ W22, W5, N/A2)
	Antiplatelet		6
	Thrombolysis		28 (UK 22, N/A 6)
	Percutaneous transluminal angioplasty		10
	SVC filter		7
	Mechanical thrombectomy		1
	Transcatheter aspilation		1
	Surgery†		6
	~Maintenance		
	Anticoagulation (W)		31
	Antiplatelet		7
	Anticoagulation (W)+Antipletelet		4
	N/A		8
Pulmonary thromboembolism			10
Lesion findings			
	Before treatment	Occlusion	28
		Stenosis	3
		N/A	18
	After treatment	Improve**	11
		No change‡	6
		N/A	32
	Chronic state	Patent	9 (1 month~2 years)
		Occlusion	1 (3 years)
		N/A	39
Clinical progress		Improve	44
		No change	1
		N/A	4
Recurrence		None	11 (2 months~2.7 years)
		N/A	38

*: mean±SD; †: surgical therapy was resection of the first rib (3 cases), surgical thrombectomy (2 cases) and surgical ligation of cephalic vein (1 case); **: occlusion to residual stenosis; ‡: occlusion (before treatment) to occlusion (after treatment) and stenosis (before treatment) to residual stenosis (after treatment)

AXV: Axillary vein; BRCV: Brachiocephalic vein; BRV: Brachial vein; H: Heparin; N/A: not available; SCV: Subclavian vein; SVC filter: Temporary superior vena cava filter; UK: Urokinase; W: Warfarin

and the lower group was 34 (11.1%). The difference had a statistically higher association with cancer in the UEDVT group than LEDVT ($p<0.01$). Most, 7 of the 9 UEDVT patients with diagnosed cancer were discovered during the first week of hospital admission.[6] So regular medical checkup for malignancy will be conducted in our outpatient clinic.

Generally, if DVT symptoms had been present for greater than 7 days, thrombolysis has a poor response. Summarized in 8 literatures, the candidate of systemic thrombolysis should be within 7 days and the optimal candidate was within 3 days of the onset.[7] This patient had a no floating thrombus in the left proximal upper-extremity vein and was without PTE, and one week had already passed since the onset, so we defined that initial anticoagulation therapy should be performed without combination of thrombolytic agents. Recently some literature reported usefulness of catheter-directed thrombolysis and percutaneous mechanical thrombectomy with the AngioJet (Possis Medical Inc., USA).[8,9] Two therapies also reduces the doses and duration of therapy. These therapies may be benefical for this case. PTE complicated with this syndrome is not rare, the incidence has been reported in about 36% of cases depending on the diagnosis made.[2] Although some literatures reported usefulness of filter placement in superior vena cava,[10] in our case filter placement was not performed because of no findings of high embolic risk factor such as floating thrombus.

Paget-Schroetter syndrome should always be kept in mind if a young healthy man has the upper-extremity edema without obvious triggers. And the screening of occult cancer as a predisposing thrombotic factor should be required.

References

1. Hicken GJ, Ameli M. Management of subclavian-axillary vein thrombosis: a review. Can J Surg 1998;41:13-25.
2. Joffe HV, Goldhaber SZ. Upper-extremity deep vein thrombosis. Circulation 2002;106:1874-80.
3. Martenelli I, Battaglioli T, Bucciarelli P, et al. Risk factors and recurrence rate of primary deep vein thrombosis of the upper extremities. Circulation 2004;110:566-70.
4. Bliss S, Weinberger S, Meier M, et al. The unusual suspect. N Engl J Med 2002;347:1876-81.
5. Sorensen HT, Mellemkjaer L, Steffensen H, et al. The risk factor of a diagnosis of cancer after diagnosis of after primary deep venous thrombosis or pulmonary embolism. N Engl J Med 1998;338:1169-73.
6. Girolami A, Prandoni P, Zanon E, et al. Venous thromboses of upper limbs are more frequency associated with occult cancer as compared with those of lower limbs. Blood Coag Fibrinol 1999;10:455-7.
7. Guidelines for the diagnosis, treatment and prevention of pulmonary thromboembolism and deep vein thrombosis. JCS 2004;68:1079-134.
8. Fraschini G, Jadeja J, Lawson M, et al. Local infusion of urokinase for the lyisis of thrombosis assiciated with permanent central venous catheters in cancer patients. J Clin Oncol 1987; 5:672-8.
9. Kasirajan K, Gray B, Ouriel K. Percutaneous AngioJet thrombectomy in the management of extensive deep venous thrombosis. J Vasc Interv Radiol 2001;12:179-85.
10. Spence LD, Gironta MG, Malde HM, et al. Acute upper extremity deep venous thrombosis: safety and effectiveness of superior vena caval filters. Radiology 1999;210:53-8.