ECG Quiz

KWOK-KEUNG CHAN, TAT-CHI LEUNG

From Department of Medicine, Pamela Youde Nethersole Eastern Hospital, Hong Kong

A 37-year-old man presented to the Accident and Emergency Department for palpitation and shortness of breath. He experienced two similar episodes of fast palpitation in the past 6 months, each episode lasting for a few hours. There was no history of syncope or angina. Past health and family history were unremarkable.

The patient was conscious and alert on presentation, with a blood pressure 120/84 mmHg. ECG (Figure 1) was performed, showing a regular tachycardia of 230/minute. A provisional diagnosis of supraventricular tachycardia (PSVT) with aberration was made. The tachycardia was not responsive to intravenous adenosine. Amiodarone infusion 150 mg over 15 minutes converted it to sinus rhythm (Figure 2). Subsequent investigations including blood-tests, chest XR and echocardiography were normal.

What could be the differential diagnoses?

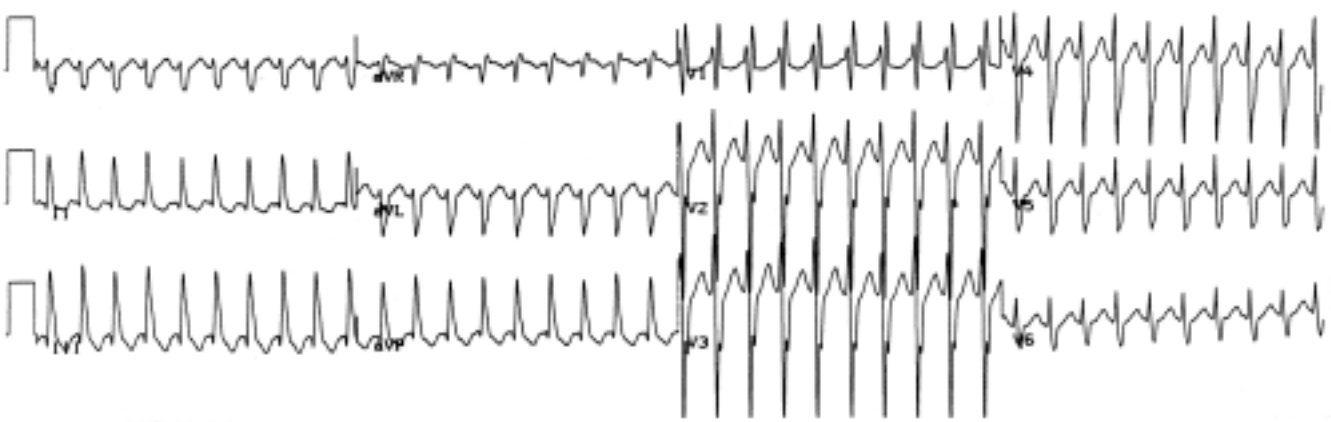

Figure 1. *Presenting tachycardia*

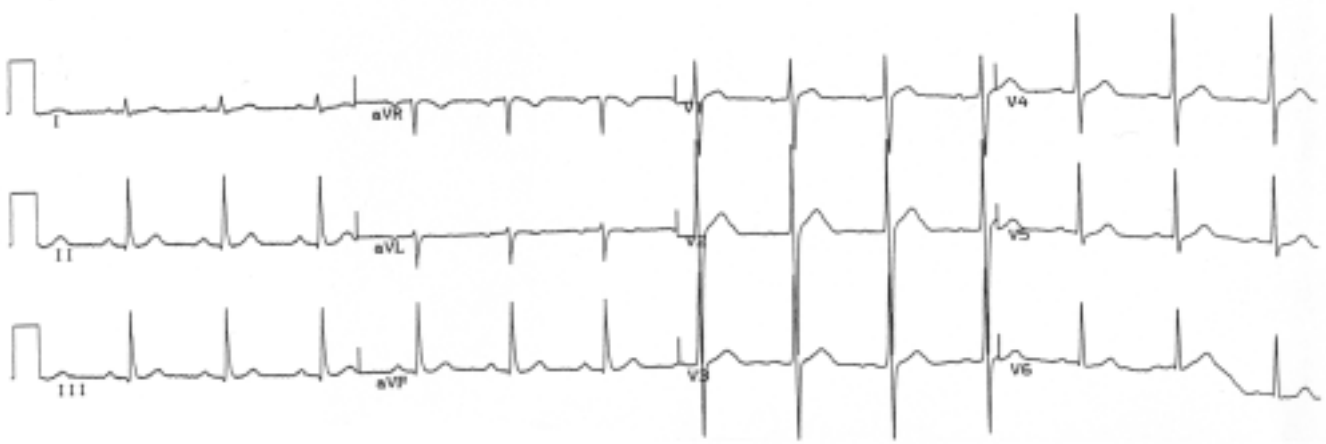

Figure 2. *Sinus rhythm*

Discussion

The presenting arrhythmia was a regular tachycardia (230/minute) with a right bundle branch block (RBBB) configuration and right-axis deviation. The QRS duration was 96 ms by computer analysis. There were no dissociated P waves, capture or fusion beats noted. These features might suggest a diagnosis of PSVT with aberration in a healthy young patient with no structural heart disease. The tachycardia, however, was not responsive to intravenous adenosine. Previous studies[1-3] showed that the success rate for conversion of PSVT to sinus rhythm by adenosine ranged from 93.4% to 100%. One might consider an uncommon diagnosis of idiopathic ventricular tachycardia as a differential diagnosis.

An electrophysiological (EP) study was subsequently performed. At isoprenaline infusion 3 μg/minute, right ventricular overdrive pacing reproducibly induced a tachycardia with a cycle length of 260 ms and a morphology identical to the clinical arrhythmia. The presence of ventriculoatrial dissociation confirmed that it was ventricular tachycardia (VT). The diagnosis was left anterior fascicular VT, which was an uncommon form of idiopathic left ventricular tachycardia. It was characterized by VT with a RBBB configuration and right-axis deviation in a structurally normal heart. The tachycardia was responsive to verapamil but not adenosine. A more common form of idiopathic left ventricular tachycardia was VT with a RBBB configuration and left-axis deviation, which was originated from the left posterior fascicle.

During radiofrequency (RF) ablation, endocardial mapping at the anterolateral wall of the left ventricle during VT identified the earliest ventricular activation 35 ms before the onset of QRS complex (Figure 3A). RF energy applications at this site (the exit site) were unsuccessful. A Purkinje potential (a short-duration, high-frequency potential preceding earliest ventricular activation) of 30 ms earlier than QRS onset (Figure 3B) was noted at a nearby site. RF ablation was not successful. Eventually RF ablation at the mid-anterior septum with Purkinje potential in the diastolic phase during VT (zone of slow conduction) (Figure 3C) eliminated the tachycardia and prevented its reinduction by programmed stimulation with isoprenaline infusion.

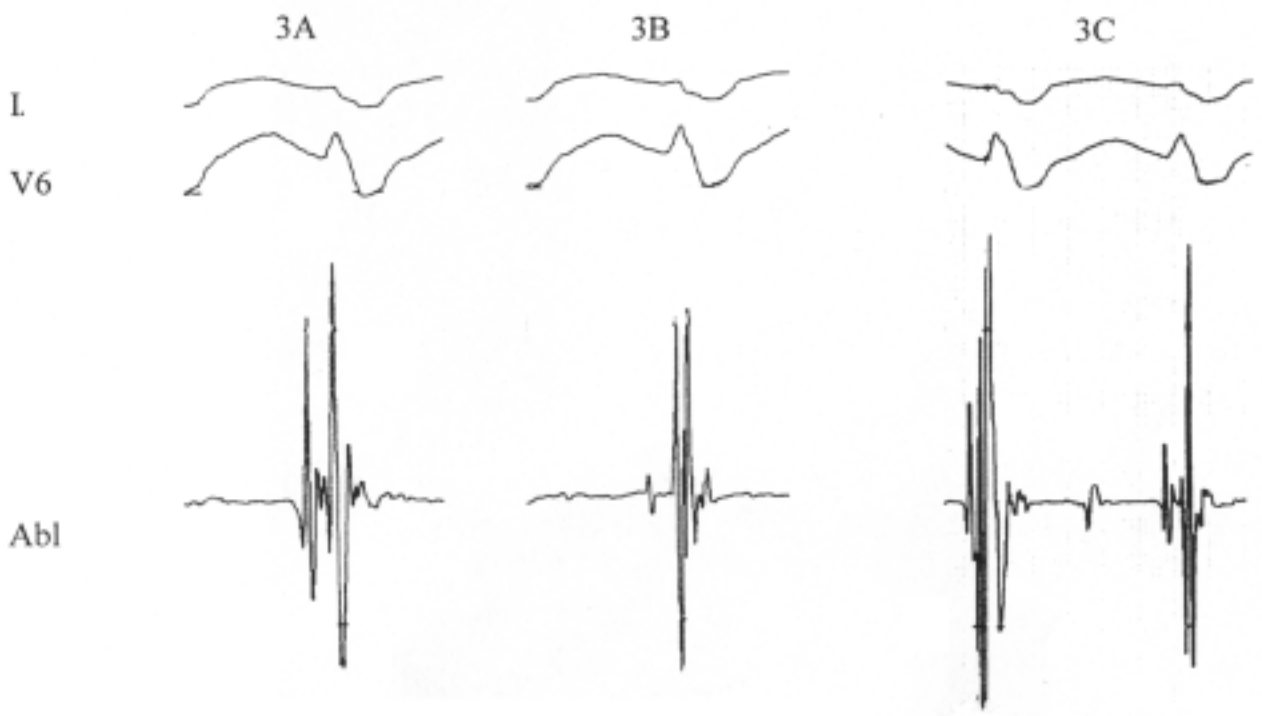

Figure 3. *Endocardial mapping during VT: (A) Earliest ventricular activation (B) Presystolic Purkinje potential (C) Diastolic Purkinje potential.*

The patient was discharge uneventfully and there was no recurrence of tachycardia after a follow-up of 9 weeks.

Nogami et al[4] demonstrated that left anterior fascicular VT was induced and terminated by ventricular pacing and entrainment phenomenon was present, suggesting reentrant tachycardia as the mechanism. Bogun et al[5] reported one patient with left anterior fascicular VT in whom RF ablation was successful at the anterobasal wall of left ventricle with Purkinje potential despite poor pace mapping. Rodriguez et al[6] used a Purkinje potential and an optimal pacemap as a guide for successful ablation in one patient. Nogami et al[4] reported successful RF ablation in 6 patients with left anterior fascicular VT. In 3 of 6 patients, RF was successful at the exit site where the earliest ventricular activation was recorded with a Purkinje potential. In the remaining 3 patients, RF energy delivered at the zone of slow conduction with the diastolic Purkinje potential eliminated the VT. He concluded that a diastolic Purkinje potential during VT was more helpful than endocardial ventricular activation or pace mapping in identifying an effective ablation site. Other investigators,[7] however, found that a combination of activation and pace mapping remained the most efficacious method for identifying successful ablation site.

The exact nature of the reentry circuit in idiopathic left ventricular tachycardia, however, was unclear. Previous studies have tried to clarify this problem. Wen et al[8] performed successful ablation of idiopathic left ventricular tachycardia in 7 patients at sites away from the tachycardia exit site. He suggested that the reentry circuit was likely to be of considerable size, extending from the mid septum to the inferior apical septum of left ventricle. Nogami et al[9] studied 20 patients with left posterior fascicular VT. He demonstrated that both the presystolic and diastolic Purkinje potentials were critical potentials in the macroreentry circuit involving the normal and abnormal Purkinje tissue respectively. He further hypothesized that the mechanism for both left anterior and posterior fascicular VT might be similar and both could be cured by RF ablation.

References

1. DiMarco J, Miles W, Akhtar M, et al. Adenosine for paroxysmal supraventricular tachycardia: Dose ranging and comparison with verapamil. Ann Intern Med 1990;113:104-10.
2. Hood MA, Smith WM. Adenosine versus verapamil in the treatment of supraventricular tachycardia: A randomized double-crossover trial. Am Heart J 1992;123:1543-9.
3. Garratt C, Linker N, Griffith M, et al. Comparison of adenosine and verapamil for termination of paroxysmal junctional tachycardia. Am J Cardiol 1989;64:1310-6.
4. Nogami A, Naito S, Tada H, et al. Verapamil-sensitive left anterior fascicular ventricular tachycardia: Results of radiofrequency ablation in six patients. J Cardiovasc Electrophysiol 1998;9:1269-78.
5. Bogun F, El-Atassi R, Daoud E, et al. Radiofrequency ablation of idiopathic left anterior fascicular tachycardia. J Cardiovasc Electrophysiol 1995;6:1113-6.
6. Rodriguez L, Smeets J, Timmermans C, et al. Radiofrequency catheter ablation of idiopathic ventricular tachycardia originating in the anterior fascicle of the left bundle branch. J Cardiovasc Electrophysiol 1996;7:1211-6.
7. Varma N, Josephson ME. Therapy of idiopathic ventricular tachycardia. J Cardiovasc Electrophysiol 1997;8:104-16.
8. Wen MS, Yeh SJ, Wang CC, et al. Successful radiofrequency ablation of idiopathic left ventricular tachycardia at a site away from the tachycardia exit. J Am Coll Cardiol 1997;30:1024-31.
9. Nogami A, Naito S, Tada H, et al. Demonstration of diastolic and presystolic Purkinje potentials as critical potentials in a macroreentry circuit of verapamil-sensitive idiopathic left ventricular tachycardia. J Am Coll Cardiol 2000;36:811-23.