Clinical Experience of Contrast Venography Guided Axillary Vein Puncture for Placement of Pacemaker and Defibrillator Leads in Chinese Patients

NGAI-YIN CHAN, NGAI-SHING MOK, CHI-WO WU, WAI-SUEN LEUNG, PING-TIM TSUI, MIU-FONG KWOK, CHI-CHUNG CHOY

From Cardiology Team, Department of Medicine & Geriatrics, Princess Margaret Hospital, Hong Kong

CHAN ET AL.: ***Clinical Experience of Contrast Venography Guided Axillary Vein Puncture for Placement of Pacemaker and Defibrillator Leads in Chinese Patients. Background and Objectives:*** *Subclavian crush phenomenon is associated with lead placement using subclavian puncture (SP). Cephalic venous cutdown (CV), free of this complication, may be too small for use or just not big enough for multiple leads placement as in biventricular pacing or dual site atrial pacing. Contrast venography guided axillary vein puncture (AP) has been described to solve this problem. This study reports on clinical experience of this technique in Chinese patients.* ***Methods:*** *AP has been introduced in Princess Margaret Hospital since 1/7/00. Patient characteristics, effectiveness, safety and implantation time are analysed. Sizes of axillary, subclavian and cephalic veins are compared.* ***Results:*** *AP was performed in 28 patients, 11 male and 17 female with mean age 64.9±14.3 years from 1/7/00 to 30/9/01. Sixteen patients had dual chamber pacing, 1 single chamber pacing, 6 biventricular pacing, 1 dual site atrial pacing, 1 single chamber upgrade to dual chamber pacing, 2 single chamber and 1 dual chamber ICD implantation. AP was successful in 26/28 (92.9%) patients. One failure was due to venous tortuosity which was then bypassed by SP. The other failure was due to small size of axillary vein and SP was then used. Implantation time using AP was not significantly different from a nonAP group of 44 patients using SP or CV during same period. (113±27.2 vs 125.3±47.3 min, p=0.105) There were no AP related complications. Using venography, axillary vein is comparable to subclavian vein in size. (8.7±2.2 vs 9.7±2.3 mm, p=0.114) Cephalic vein is significantly smaller than axillary or subclavian vein. (3.6±1.3 mm, p<0.001).* ***Conclusions:*** *AP is both effective and safe for pacemaker or defibrillator lead placement. Multiple leads placement is possible in view of comparable size of axillary vein to subclavian vein. And implantation time using AP is similar to using other techniques. AP should therefore be complementary to other approaches for lead placement. (J HK Coll Cardiol 2002;10:74-80)*

Axillary vein puncture, contrast venography, defibrillator lead placement, pacemaker lead placement

摘要

背景和目的：鎖骨下靜脈損傷與經鎖骨下靜脈穿刺置入電極有關。頭靜脈切開雖可避免這種併發症，但對於雙室起搏或雙部位心房起搏而需置入多個電極時血管偏小。靜脈造影指導下的腋靜脈穿刺術可克服這一問題。本研究報告中國人經此技術置入的臨床經驗。方法：自 2000 年 7 月以來在瑪嘉烈醫院開始採用腋靜脈穿刺途徑，分析患者的

Address for reprints: Dr. Ngai-Yin Chan
Cardiology Team, Department of Medicine and Geriatrics, Princess Margaret Hospital, Princess Margaret Hospital Road, Kowloon, Hong Kong

Tel: (852) 2990 1111, Fax: (852) 2990 3329

Received November 16, 2001; revision accepted December 20, 2001

特徵、操作的有效性、安全性和安置時間，並比較了腋靜脈、鎖骨下靜脈和頭靜脈的大小。**結果**：自 2000 年 7 月 1 日至 2001 年 9 月 30 日，採用靜脈穿刺途徑的患者 28 例，男 11 例、女 17 例，平均年齡 64.9 ± 14.3 歲。16 例雙腔起搏、1 例單腔起搏、6 例雙室起搏、1 例雙心房起搏、1 例單腔起搏後改為雙腔起搏、2 例單腔和 1 例雙腔 ICD 置入。經腋靜脈穿刺途徑成功 26 例（92.2%）。1 例因腋靜脈扭曲改為鎖骨下靜脈穿刺途徑，另 1 例因腋靜脈細小而改為鎖骨下靜脈穿刺術。腋靜脈穿刺組與 44 例以鎖骨下靜脈或頭靜脈穿刺的非腋靜脈穿刺組比較，其安置時間無明顯差異（113±27.2 比 125.3±47.3 分鐘，p=0.105）。無腋靜脈穿刺有關的並發症。靜脈造影顯示腋靜脈的大小與鎖骨下靜脈相當（8.7±2.2 比 9.7±2.3 mm，p=0.114）。頭靜脈較腋靜脈或鎖骨下靜脈明顯細小(3.6±1.3 mm，p<0.001)。**結論**：經腋靜脈穿刺置入起搏器或除顫電極既安全又有效。與鎖骨下靜脈大小相當的腋靜脈，可穿刺置入多個電極，且經腋靜脈穿刺置入電極的時間與其他途徑相近。經腋靜脈穿刺途徑應是其他部位穿刺置入電極的替代方法。

關鍵詞：腋靜脈穿刺　　靜脈造影　　除顫電極安置　　起搏電極安置

Introduction

The choice of vascular access for endocardial lead placement in device implantation has been evolving since the first successful use of temporary transvenous pacing via the brachial vein in 1959.[1] The cephalic cutdown approach was introduced in the late 1960s[2,3] and has remained one of the standard approaches for endocardial lead insertion since then. Anatomical approach of subclavian vein puncture became another possible approach with the introduction of peel away sheath.[4] Large scale survey of cardiac pacing in United States revealed that the subclavian approach is most widely practised.[5] However, various acute complications including a 1-3% incidence of pneumothorax or hemothorax have been described.[6-8] In addition, subclavian crush phenomenon, which is a longer term complication of lead fracture due to entrapment by the costoclavicular ligament and/or the subclavius muscle, has been well described.[9-12]

Because of the potential disadvantages in using subclavian approach for endocardial lead placement and the significant failure rate of cephalic vein cutdown,[13,14] a modified cephalic vein cutdown approach which leads to a success rate of 76% was reported recently.[15] The modified approach still leaves room for a complementary venous access. On the other hand, cephalic vein alone is most unlikely to be suitable for multiple endocardial leads placement in biventricular or multisite atrial pacing.

A number of techniques have been developed to aid access for the axillary vein. These include anatomical approach,[16] fluoroscopy guided approach,[17] ultrasound guided approach,[18] doppler guided approach[19] and contrast venography guided approach.[20] This paper reports on the clinical experience of contrast venography guided axillary vein puncture for placement of pacemaker and defibrillator leads in Chinese patients. Suitability of axillary vein puncture for multiple leads placement is examined by comparing the sizes of axillary vein to subclavian vein using contrast venography. On the other hand, implantation time with axillary approach is compared to other techniques.

Methods

Study Population

All patients admitted for pacemaker or ICD implantation from July 2000 to September 2001 were included in the study. Patients who did not require new lead placement, as in the case of generator revision or replacement, were excluded. Informed consent was obtained from all patients. Each system was implanted by two cardiologists. A total of six cardiologists were involved with lead placement during the course of this study. Any 2-lead or 3-lead system implantation involving the first author and one other cardiologist was accomplished by contrast venography guided axillary vein puncture; AP was used in single lead device only if cephalic venous cutdown failed (AP group). Systems implanted by other cardiologists were accomplished by cephalic venous cutdown ± subclavian puncture (nonAP group).

Technique of Contrast Venography Guided Axillary Vein Puncture

Axillary vein is a deep structure. The venae comitantes of the brachial artery unite with the basilic vein in the upper part of the arm and continue as the

axillary vein above the lower border of teres major. The vein ascends medial to the axillary artery passing behind pectoralis minor, and crosses the lateral edge of the first rib to continue as the subclavian vein, lying anterior to its companion artery. The cephalic vein is a major tributary of the axillary vein. It ascends in the deltopectoral groove. The technique of contrast venography guided axillary vein puncture has been well described.[20] Slight modification of the technique was used in our centre due to the unavailability of micropuncture introducer set. A subcutaneous generator pocket is made by an incision parallel to and 1 cm medial to the deltopectoral groove. The incision is started 2 cm below the clavicle. 10 ml of contrast is injected through an ipsilateral peripheral intravenous line and then flushed with 25 to 50 ml of normal saline. An 18-gauge puncture needle is positioned at an angle of 60 degrees to the plane of skin and parallel to the axillary vein. The needle is directed towards the vein until blood is aspirated. Introduction of a standard 50 cm 0.038-inch J- tipped guidewire and peel-away sheath are then performed by Seldinger technique. The axillary vein may be divided into a medial and lateral segment as defined by the rib cage margin. Axillary puncture is performed by aiming at the lateral segment first because of a practically zero risk of pneumothorax. Failing that, the medial segment of the vein is punctured.

Data Analysis

Patient characteristics, effectiveness, safety and implantation time of the technique were analysed. Diameters of axillary, subclavian and cephalic vein were compared by measurement during contrast venography. Continuous variables are expressed as mean±1 SD. Statistical differences of continuous variables were analysed with Student's t test. A p value <0.05 was considered significant.

Results

AP was attempted in 28 patients. There were 11 male and 17 female patients with mean age of 64.9±14.3 years. Sixteen patients had dual chamber pacing, 1 single chamber pacing, 6 biventricular pacing, 1 biatrial pacing, 1 upgrade from single to dual chamber pacing, 2 single chamber and 1 dual chamber ICD implantation.

Figure 1 shows a typical contrast venography of axillary vein in one of our patients. AP was

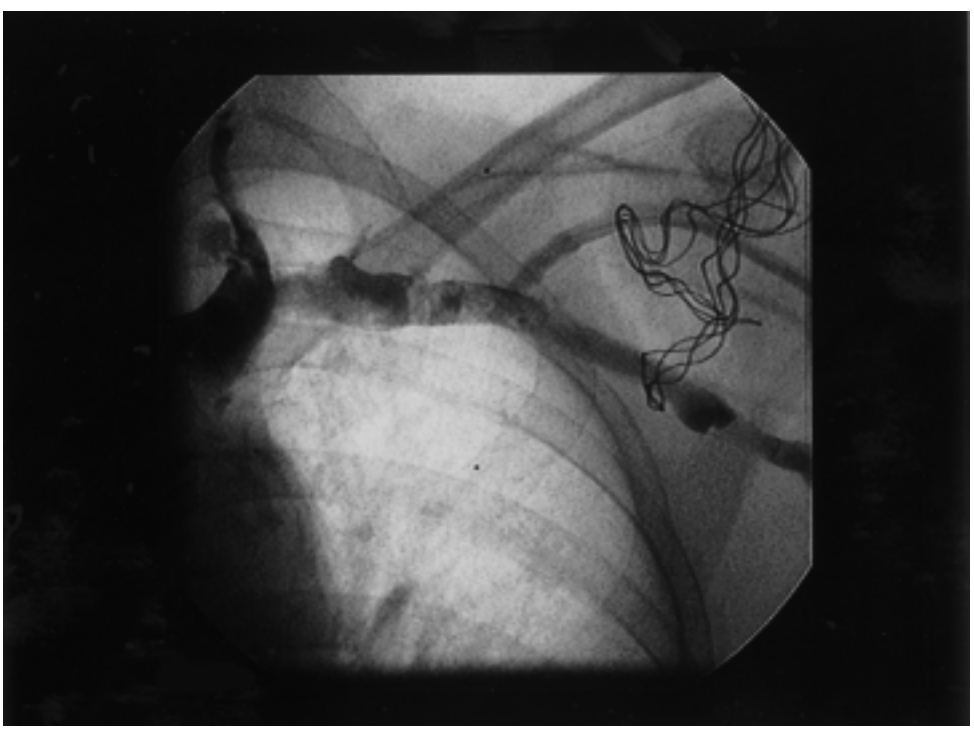

Figure 1. *Typical contrast venography of the axillary vein.*

successful in 26/28 (92.9%) patients. One failure was due to tortuosity of the axillary vein (Figures 2a and 2b). The axillary vein was punctured without difficulty. However, guidewire failed to cross the tortuosity which was subsequently bypassed by subclavian puncture. Another failure was due to small size of the axillary vein (Figure 3). Subclavian puncture was then performed successfully. There were no AP related or contrast related complications.

The mean implantation time, which is defined as skin-to-skin time, was 113.1±27.2 minutes in AP group. In the nonAP group of 44 patients, the mean implantation time was 125.3±47.3 minutes when cephalic vein cutdown ± subclavian puncture was performed during the same period as the AP group. There is no statistically significant difference (p=0.105).

In order to compare the sizes of axillary, subclavian and cephalic vein by contrast venography, the following definitions were used. The diameter of the axillary vein was defined as the average of its diameters at the rib cage margin and the lateral border of first rib. The diameter of the subclavian vein was defined as the average of its diameters at the lateral and medial border of the first rib. The diameter of the cephalic vein was measured at the point where it joins the axillary vein. The mean diameter of axillary, subclavian and cephalic vein was 8.7±2.2, 9.7±2.3 and 3.6±1.3 mm respectively. There is no statistically significant difference between the sizes of axillary and subclavian vein (p=0.114). However, the cephalic vein is significantly smaller than the axillary or subclavian vein (p<0.001).

Discussion

Main Findings

Vascular access is a prerequisite step in device implantation. Subclavian vein puncture has the beauty of being simple and quick to use. Unfortunately, it is associated with both acute and longer term complications.[6-12] Subclavian crush phenomenon can be a serious complication especially in ICD systems.[12] Cephalic vein cutdown, free of this complication, can still fail in 25-50% of cases.[13,14] With a modified approach, causes of failure of cephalic vein cutdown include difficult cephalic vein isolation, venous stenosis, venous tortuosity or anomalies.[15] In addition, cephalic vein alone is most unlikely to accommodate multiple leads in biventricular pacing or multisite atrial pacing.

The results of the present study shows that contrast venography guided axillary vein puncture is both effective and safe for pacemaker or defibrillator lead placement in Chinese patients. This technique has been described[20] and the success rate in our study was 92.9% which is comparable to the other report. There were no complications related to using this technique. There were two failures in a total of 28 attempts. One failure was due to tortuosity of the axillary vein which was successfully bypassed by subclavian vein puncture. The other failure was due to small size of the axillary vein. Again, subclavian puncture was performed successfully for lead placement. These causes of failure, however, were not experienced by the author of the above report. The implantation time while using axillary puncture was not significantly longer than when other techniques for venous access were used. Using venography, sizes of axillary, subclavian and cephalic veins were compared. To the best of our knowledge, no previous studies have addressed to this point yet. There was no statistically significant difference between the diameters of axillary and subclavian veins. However, the cephalic vein is significantly smaller than either the axillary or subclavian vein. This has important clinical implications when multiple leads placement is concerned.

Clinical Implications

Biventricular pacing is an evolving treatment modality for heart failure patients.[21] On the other hand, dual site atrial pacing and biatrial pacing are potential treatments for atrial fibrillation.[22] Both of these pacing therapies require implantation of three leads. Cephalic vein alone is most unlikely to satisfy such requirement. Subclavian vein, which is big enough, has its own disadvantages as mentioned before. Contrast venography guided axillary vein puncture is an attractive alternative. According to the present study, the fact that axillary vein is comparable to subclavian vein in size is supportive for this idea. Axillary puncture was used in 6 patients who had biventricular pacing in this study and there was one failure due to venous tortuosity. This technique is

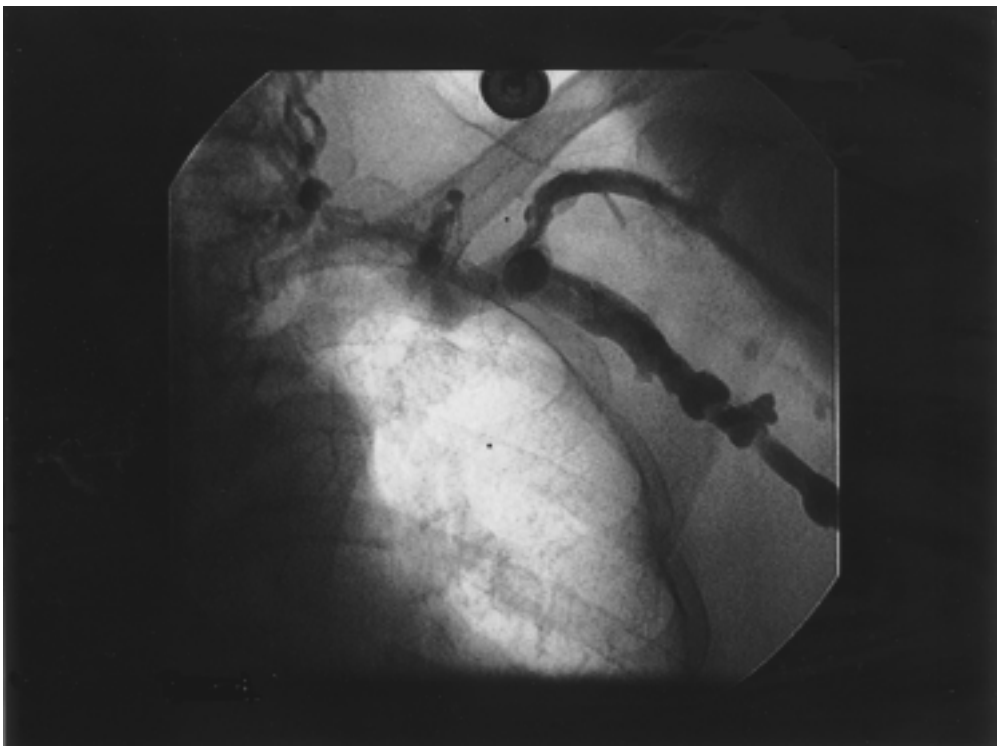

Figure 2a. *Contrast venography of a tortuous axillary vein - AP view.*

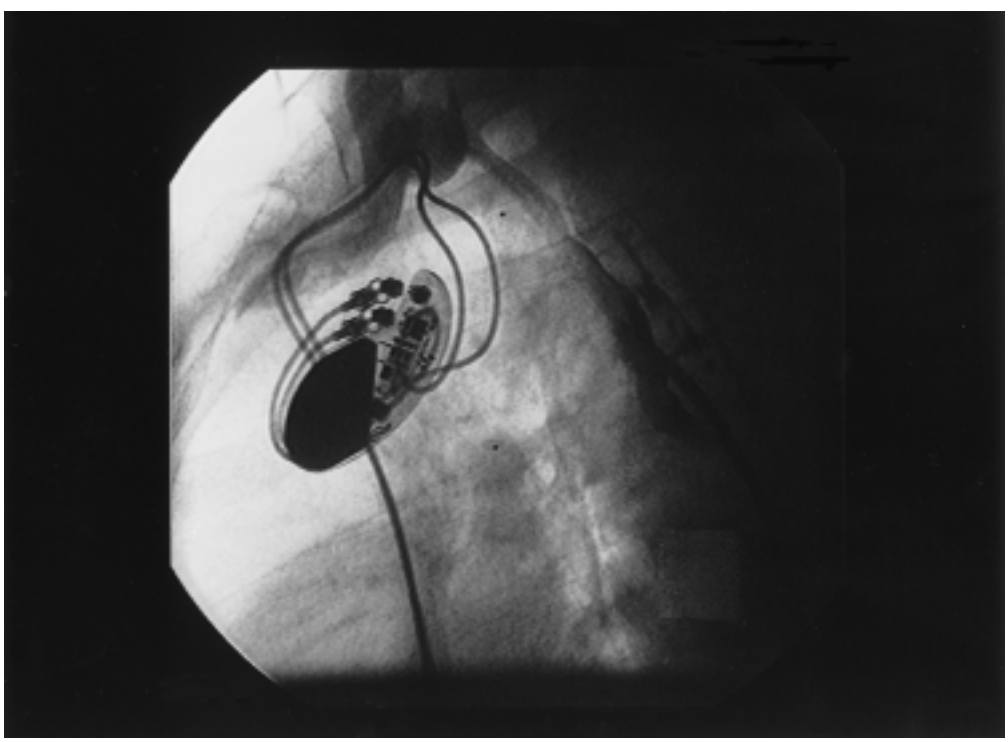

Figure 2b. *Contrast venography of a tortuous axillary vein - Lateral view.*

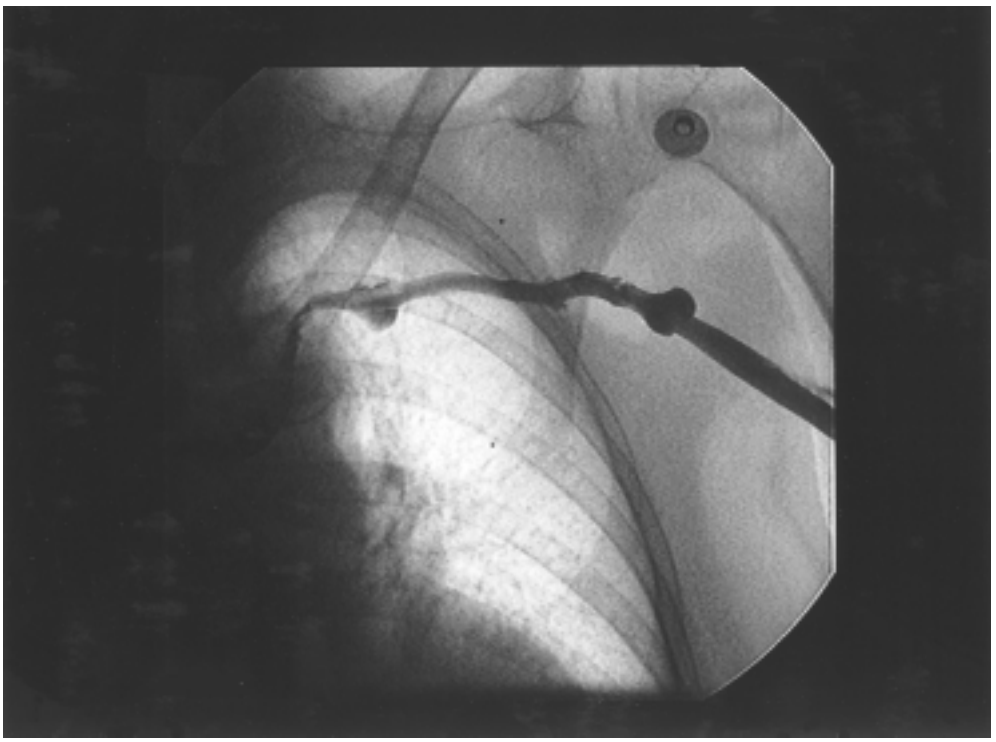

Figure 3. *Contrast venography of a small axillary vein.*

probably the method of choice in multiple leads placement. However, the use of this technique for multiple leads placement requires further study.

Contrast venography guided axillary puncture is both effective and safe for pacemaker or defibrillator lead placement as shown by the present study and the others. However, the exact position of axillary puncture among other techniques as venous access for endocardial lead placement is still unknown. A recent study prospectively compared the safety and effectiveness of placement of endocardial pacemaker and defibrillator leads using the extrathoracic subclavian vein guided by contrast venography versus the cephalic approach.[23] The contrast venography guided extrathoracic subclavian vein approach resulted in a higher success rate, shorter procedure time and less blood loss. The cephalic vein cutdown technique may be used for single lead device implantation and axillary puncture technique can be used otherwise or in case of failure with cephalic approach.

Study Limitations

This is only a retrospective study in a small number of patients who belong to a heterogenous population. As a result, difference in implantation time between AP and nonAP group cannot be accurately compared. Furthermore, implantation time depends very much on the experience of operators. On the other hand, absence of statistically significant difference in the diameters of axillary and subclavian vein may be simply due to a small sample size. Axillary puncture was performed by one operator who is experienced in this technique. Similar results may only be achieved after a learning period. Lastly it has to be remembered that use of contrast is associated with a potential risk of anaphylactic reaction.

References

1. Furman S, Schwedel JB. An intracardiac pacemaker for Stokes-Adams seizures. N Engl J Med 1959;261:943-8.

2. Parsonnet V, Zucker R, Gilbert L, et al. Clinical use of an implantable standby pacemaker. JAMA 1966;196:784-6.
3. King SM, Arrington JO, Dalton ML. Permanent transvenous cardiac pacing via the left cephalic vein. Ann Thorac Surg 1968; 5:469-73.
4. Mobin-Uddin K, Smith PE, Lombardo C, et al. Percutaneous intracardiac pacing through the subclavian vein. J Thorac Cardiovasc Surg 1967;54:545-8.
5. Bernstein AD, Parsonnet V. Survey of cardiac pacing in the United States in 1989. Am J Cardiol 1992;69:331-8.
6. Aggarwal RK, Connelly DT, Ray SG. Early complications of permanent pacemaker implantation: no difference between dual and single chamber systems. Br Heart J 1995;73:571-5.
7. Chauhan A, Grace AA, Newell SA, et al. Early complications after dual chamber versus single chamber pacemaker implantation. Pacing Clin Electrophysiol 1994;17(11 Pt 2):2012-5.
8. Parsonnet V, Bernstein AD, Lindsay B. Pacemaker-implantation complication rates: an analysis of some contributing factors. J Am Coll Cardiol 1989;13:971-21.
9. Kazama S, Nishiyama K, Machii M, et al. Long-term follow up of ventricular endocardial pacing leads. Complications, electrocal performance, and longevity of 561 night ventricular leads. Jpn Heart J 1993;34:193-200.
10. Jacobs DM, Fink AS, Miller RP, et al. Anatomical and morphological evaluation of pacemaker lead compression. Pacing Clin Electrophysiol 1993;16(3 Pt 1):434-44.
11. Magney JE, Flynn DM, Parsons JA, et al. Anatomical mechanisms explaining damage to pacemaker leads, defibrillator leads, and failure of central venous catheters adjacent to the sternoclavicular joint. Pacing Clin Electrophysiol 1993;16(3 Pt 1):445-57.
12. Roelke M, O'Nunain SS, Osswald S, et al. Subclavian crush syndrome complicating transvenous cardioverter defibrillator systems. Pacing Clin Electrophysiol 1995;18(5 Pt 1):973-9.
13. Furman S. Cardiac pacing and pacemaker. In WWL Glenn, AE Baue, AS Geha, et al. (eds.): Thoracic and Cardiovascular Surgery. 4th ed. New York, Appleton-Century-Crofts, 1983, pp. 1228-1262.
14. Furman S. Venous cutdown for pacemaker implantation. Ann Thorac Surg 1986;41:438-9.
15. Tse HF, Lau CP, Leung SK. A cephalic vein cutdown and venography technique to facilitate pacemaker and defibrillator lead implantation. Pacing Clin Electrophysiol 2001;24(4 Pt 1): 469-73.
16. Magney JE, Staplin DH, Flynn DM, et al. A new approach to percutaneous subclavian venipuncture to avoid lead fracture or central venous catheter occlusion. Pacing Clin Electrophysiol 1993;16:2133-42.
17. Belott PH. Unusual access sites for permanent cardiac pacing. In Barold SS, Mujica J, eds. Recent Advances in Cardiac Pacing: Goals for the 21st Century, Vol. 4. Futura Publishing Co., Inc, Armonk, NY, 1998, pp 137-180.
18. Gayle DD, Bailey JR, Haistey WK, et al. A novel ultrasound-guided approach to the puncture of the extrathoracic subclavian vein for surgical lead placement. Pacing Clin Electrophysiol 1996;19:700.
19. Fyke FE 3 rd. Doppler-guided extrathoracic introducer insertion. Pacing Clin Electrophysiol 1995;18(5 Pt 1):1017-21.
20. Ramza BM, Rosenthal L, Hui R, et al. Safety and effectiveness of placement of pacemaker and defibrillator leads in the axillary vein guided by contrast venography. Am J Cardiol 1997;80: 892-6.
21. Cazeau S, Leclercq C, Lavergne T, et al. Effects of multisite biventricular pacing in patients with heart failure and intraventricular conduction delay. N Engl J Med 2001;344:873-80.
22. Saksena S, Delfaut P, Prakash A, et al. Multisite electrode pacing for prevention of atrial fibrillation. J Cardiovasc Electrophysiol 1998;9:S155-62.
23. Calkins H, Ramza BM, Brinker J, et al. Prospective randomized comparison of the safety and effectiveness of placement of endocardial pacemaker and defibrillator leads using the extrathoracic subclavian vein guided by contrast venography versus the cephalic approach. Pacing Clin Electrophysiol 2001; 24(4 Pt 1):456-64.