ECG Quiz

STEVE WAI-KEUNG LAI

From Division of Cardiology, Department of Medicine & Geriatrics, Tuen Mun Hospital, Hong Kong

A 68-year-old gentleman attended Accident and Emergency Department because of chest pain, breathlessness, and dizziness for 2 days. Initial ECG showed atrial fibrillation, HR 77/min, QRS duration of 118ms and Q wave over lead III and aVF. He was admitted to Coronary Care Unit (CCU) for further management. Echocardiogram showed akinetic inferior and posterior wall, with an ejection fraction of 30%. His CPK level came back to be 4230U/L. Thrombolytic therapy was not given because of delayed presentation. During initial hospital stay, he required inotrope support. Five days after admission, he developed wide complex tachycardia (Figure 1).

Under close monitoring in CCU, carotid massage and intravenous ATP bolus injection were attempted without any effect. He was given intravenous amiodarone infusion and his rhythm reverted back to sinus. Unfortunately, similar rhythm recurred and became incessant despite further loading of amiodarone. He underwent urgent coronary angiogram, which revealed mid left circumflex and distal left anterior descending artery critical stenosis, and an intracoronary thrombus was found in mid left circumflex artery. After intravenous bolus of eptifibatide, balloon angioplasty and stenting were performed to these 2 lesions. Afterwards, this wide complex tachycardia no longer persisted.

1. What is the diagnosis?

a) Sinus tachycardia with RBBB
b) Supraventricular tachycardia with aberrant conduction
c) Ventricular tachycardia

2. What would be the initial management? (Given that his blood pressure (BP) was 110/80 mmHg and he was not in distress.)

a) Observation and monitor BP
b) Carotid massage
c) Intravenous ATP bolus
d) Intravenous verapamil
e) Intravenous amiodarone
f) Immediate cardioversion

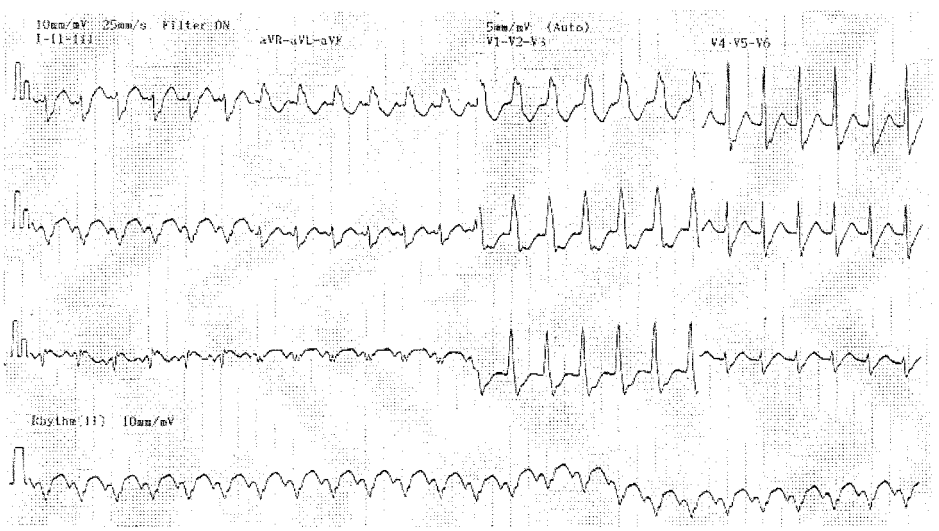

Figure 1.

Answer

1. c) Ventricular tachycardia
2. e) Intravenous amiodarone

Discussion

This gentleman suffered from wide complex tachycardia complicating recent acute myocardial infarction and poor left ventricular function. Under this circumstance, any wide complex tachycardia should be treated as ventricular tachycardia until proven otherwise. Since he was relatively asymptomatic, pharmacolgic intervention was attempted. Should he develop any sign of hemodynamic compromise or ischemic symptom, electrical cardioversion has to be considered. Verapamil is contraindicated in this situation. Although intravenous ATP is of short acting, it should be avoided as detrimental effect had been reported.[1]

This ECG shows wide complex tachycardia with RBBB morphology. Interestingly, there is a P wave preceding each QRS complex. However, the polarities of the P waves are negative in the inferior leads, which rule out sinus tachycardia. With these polarities, it can either be a retrograde P wave or atrial tachycardia from lower atrial septum.[2] Therefore the remaining differential diagnosis includes ventricular tachycardia with 1:1 retrograde VA conduction, atrial tachycardia, atrioventricular nodal re-entry tachycardia (fast-slow), or orthrodromic reciprocal tachycardia using a slow conducting accessory pathway.

Although we cannot see any AV dissociation, concordance, fusion beat, or capture beat, there are other clues leading to the diagnosis. Firstly, the axis is strange. It lies between -90° and +180°. In wide complex tachycardia, left axis deviation favors the diagnosis of VT and northwest axis points to the diagnosis of VT. Secondly, right bundle branch block QRS morphology with Rsr' pattern in V1, R/S ratio less than 1 in V6, and QRS duration greater than 140 ms suggest the diagnosis of ventricular tachycardia.[3]

In conclusion, we have a patient with recent inferior myocardial infarction developing ventricular tachycardia with retrograde 1:1 VA conduction. Care should be taken not to misdiagnose it as supraventricular tachycardia.

References

1. Parham WA, Mehdirad AA, Biermann KM, et al. Case report: adenosine induced ventricular fibrillation in a patient with stable ventricular tachycardia. J Interv Card Electrophysiol 2001;5: 71-4.
2. Tang CW, Scheinman MM, Van Hare GF, et al. Use of P wave configuration during atrial tachycardia to predict site of origin. J Am Coll Cardiol 1995;26:1315-24.
3. Chou TC, Knilans TK. Electrocardiography in Clinical Practice Adult and Pediatric 4th edition. WB Saunders, 1996.